ISSN 2320-7795
July 2013 Volume1 Issue 2

Journal of Odontological Research

Official Publication of
Indira Gandhi Institute of Dental Sciences
Nellikuzhy, Kothamangalam 686 691, Kerala, India

Journal of Odontological Research is the official publication of the Indira Gandhi Institute of Dental Sciences, Nellikuzhy P. O., Kothamangalam 686 691, Kerala. It is a peer-reviewed journal published bi-annually. The journal will cover studies related to dentistry and applied basic subjects. The articles will be published under the categories of Original Research, Review, Case Reports and Guest Column. The manuscripts for publication may be sent to the journal's e-mail : jorigids@gmail.com

Journal of Odontological Research

Official Publication of
Indira Gandhi Institute of Dental Sciences
Nellikuzhy, Kothamangalam 686 691, Kerala

EXPERT PANEL OF CONSULTANTS

TABLE OF CONTENTS

editorial

Warm Greetings from Indira Gandhi Institute of Dental Sciences...

"Coming together is a beginning, Keeping together is progress, Working together is success" With these famous lines by Henry Ford, I present before you this second issue of Journal of Odontological Research. It is indeed a matter of pride that the first issue of our institutional journal was released by Dr. Mohandas K, Hon Vice-Chancellor of Kerala University of Health Sciences in the month of February this year. This journal was the first scientific dental speciality journal to be released by a private dental college affiliated to the Kerala University of Health Sciences. The success of the first issue of this journal - a dream project of the Academic Club of our institution is reflected in the research papers received from various institutions in the country for publication in this issue.

This issue includes six original research articles, five review articles and five case reports. The original research articles include studies on radiologic imaging, cariology, dental materials, oral microbiology and epidemiological surveys on selected population. The review articles are exclusive and informative updates on current topics in diagnosis, ergonomics, dental materials and laboratory techniques. The case reports are on the diagnosis and effective management of rare clinical presentations and conditions.

I strongly appreciate the commitment and enthusiasm of all Academic Club members in bringing out this issue. A remarkable feature I could notice following the launch of this journal is that it has ignited the research aptitude lying hidden in our faculty members. I am sure that this issue will definitely be an informative yet interesting read. Wishing everyone everlasting health and happiness...

Dr. Ambika K.
Chief Editor
(Chief Patron - Academic Club)

ORIGINAL RESEARCH ARTICLE

EVALUATION OF MAGNETIC RESONANCE IMAGING FEATURES OF INTERNAL DERANGEMENT AND EFFUSION IN PATIENTS WITH UNILATERAL TEMPOROMANDIBULAR JOINT PAIN- AN IMAGING STUDY

Authors:
Anis Ahmed[1],
Prashanth Shenai K[2],
LaxmiKanth Chatra[3],
Shibu Thomas[4],
Bilahari N[5],
Sreeja P. Kumar[6].

[1]Senior Lecturer, Department of Oral Medicine and Radiology, Indira Gandhi Institute of Dental Sciences, Nellikuzhy P. O., Kothamangalam 686 691, Kerala, India.

[2]Senior Professor, Department of Oral Medicine and Radiology, Yenepoya Dental College and Hospital, University road, Deralakatte, Mangalore 575 018, Karnataka, India.

[3]Senior Professor and Head, Department of Oral Medicine and Radiology, Yenepoya Dental College and Hospital, University road, Deralakatte, Mangalore 575 018, Karnataka, India.

[4]Reader and Head, Department of Oral Medicine and Radiology, Indira Gandhi Institute of Dental Sciences, Nellikuzhy P. O., Kothamangalam 686 691, Kerala, India.

[5]Senior Lecturer, Department of Oral Medicine and Radiology, PSM College of Dental Sciences and Research, Akkikavu P. O., Thrissur, Kerala, India.

[6]Senior Lecturer, Department of Oral Medicine and Radiology, KMCT Dental College, Mampatta, Manassery P.O., Mukkam, Kozhikode 673 602, Kerala, India.

Address for correspondence:
Dr. Anis Ahmed, Senior Lecturer, Department of Oral Medicine and Radiology, Indira Gandhi Institute of Dental Sciences, Nellikuzhy P. O., Kothamangalam 686 691, Kerala, India.
E mail: dranisahmed@rediffmail.com

ABSTRACT

Background & Objectives: Among Temporomandibular disorders (TMD) Disc displacement (DD) is the most common disorder. The objective of this study was to determine the Magnetic Resonance Imaging (MRI) findings of DD and effusion in patients with unilateral TMJ pain and also to assess the relationship between TMJ pain, position of Disc and effusion.

Methods: A bilateral MRI study was conducted on 15 patients who had unilateral TMJ pain such that the contra lateral TMJ served as control. All patients were clinically examined and the intensity of pain was recorded. The patients were subjected to MRI by a 0.4 T MR scanners in open and closed mouth position. The images obtained were then interpreted by a radiologist.

Results: A total of 30 TMJ's were imaged; 15of which were symptomatic and 15 asymptomatic. A significant correlation was found between the presence of DD and TMJ pain ($p<0.005$). No significant findings were noted on effusion causing TMJ pain. There was no difference in the intensity of pain and between DD with reduction and DD without reduction. The intensity of pain in the TMJ having effusion was not significant when compared to the intensity of pain in the TMJ's not having effusion.

Conclusion: Based on the study TMJ pain is always associated with DD but not necessarily with TMJ effusion. Also the intensity of pain does not differ much based on the position of Disc or presence of effusion.

Keywords: Temporomandibular disorders; Disc displacement, Joint effusion; Magnetic Resonance Imaging.

J Odontol Res 2013;1(2):1-6

INTRODUCTION

The TMJ is a well designed fulcrum that leverages the masticatory power of muscles and dental apparatus and helps in performing multiple important functions such as those of suckling, speaking, cutting, grinding and swallowing. Though TMJ is a unique and complex joint they are vulnerable to extrinsic and intrinsic influences as well as time dependent changes like any other joints of the body. McNeill defines Temporomandibular Disorders (TMD) as a heterogeneous group of pathologies affecting the temporomandibular joints, the masticatory muscles, or both. [1] Disc displacement (DD) or Internal derangement (ID) is one of the most common forms of TMD. [2] DD is defined as an abnormal relationship between the disc and mandibular condyle involving an anterior, medial, or lateral displacement of the disc from its normal position superior to the condyle.[3] DD has been associated with pain in the TMJ, clicking and/or crepitation, headaches & limitations of jaw opening. Most painful TMJ's have a displaced disc which leads one to suspect that DD can be linked to the onset, progress or cessation of TMD related signs & symptoms.[2] Various studies have also demonstrated an association between the presence of increased fluid density in the joint space and the presence of TMJ DD.[4] It is speculated that this increased fluid density or effusion (magnetic resonance imaging findings of a hyper intensity signal inside the joint space) as such represents a pathological inflammatory process within the TMJ's that causes TMJ pain.[2] MRI provides information of the articular disc, surrounding soft tissue structures and also can reveal the presence of joint effusion. The technique is non-invasive and does not use ionizing radiation. Recent publications report MRI as a golden imaging technique for TMJ imaging. [5] So if an association between the presence of DD and joint effusion to painful joint could be established, this could be the basis for valuable additional diagnostic information from MR imaging of the TMJ. Thus the purpose of present study is to assess whether the MRI findings of TMJ DD and TMJ effusion can be associated with TMJ pain.

Methodology

Ethics: The proposed study is an interventional study in which patients are subjected to MRI and therefore ethical consent was obtained from the ethical committee before the commencement of the study.

Study design: 15 patients who were diagnosed with Unilateral TMJ pain during palpation or function and/or assisted or unassisted mandibular opening was taken as the sample. The contralateral, non-painful TMJ served as the matched control. Patients with degenerative joint disease, collagen vascular disease, TMJ trauma, developmental TMJ disorder and patients having cardiac pace maker were excluded.

Method of collection of data: The symptomatic patients were subjected to Visual Analogue Scale (VAS) for assessing the severity of pain. This was followed by a standardized clinical head and neck examination that included functional and structural examination of both joints followed by palpation of the TMJ and muscles of mastication.

The condition of the painful joint was categorized according to the following diagnoses:

1. Anterior disc displacement with reduction (ADDWR).
2. Anterior disc displacement without reduction (ADDWOR).
3. Inflammatory conditions such as synovitis / capsulitis.

Bilateral TMJ MR Images were obtained of all patients included in the study by means of 0.4 T MR scanners (APERTO, Hitachi, Singapore) and a dedicated circular polarized transmit and receive joint coil. The data was collected on a 1024×1024 matrix with a field view of 220mm. Axial localizing images were taken from which the sagittal and coronal planes were prescribed. Both close mouthed and open mouthed images were obtained. Pulse sequences were obtained on sagittal and coronal T_1 weighted images, T_2 weighted images, proton density images (PD) and Gradient Echo (GRE) weighted images. The position of the disc was diagnosed by a single radiologist for all the patients as:

Normal: when the disc was located superior to the condyle both in closed and open mouth position.
Disc displacement with reduction: when the disc was displaced at the closed-mouth position and in the normal position in the open-mouth images.

Disc displacement without reduction: when the disc was displaced in both the closed- and open-mouth positions.

Effusion: On T2-weighted images, joint effusion was identified as an area of high signal intensity in the region of the upper or lower joint spaces.

RESULTS

Age& Gender distribution - Of the total 15 patients, 4 were males and 11were females. The mean age of male patients were 22.25 and the mean age of female patients were 23.18.

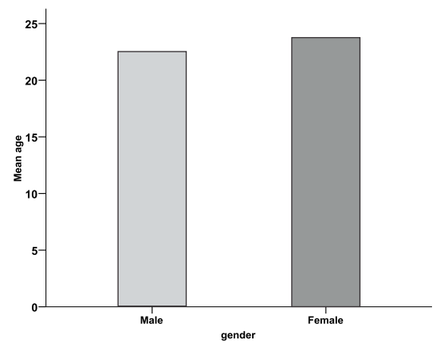

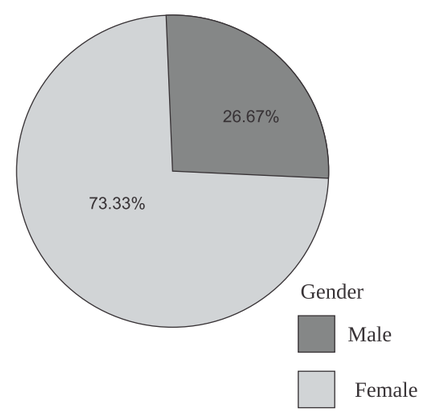

Position of disc in patients with unilateral TMJ pain- Out of 30 joints 10 joints had anteriorly placed disc (33.3%), 2 joints had anteriomedially placed disc(6.7%) and 3 joints had anteriolaterally placed disc (10%). All this displaced disc were noted in pain side and this makes 50% of the total TMJ's displaced. The rest of the TMJs on the asymptomatic side had superiorly placed disc or the disc was in normal position.

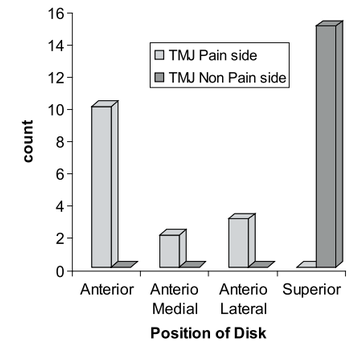

MRI findings of effusion in patients with unilateral TMJ pain- In patients who had no pain there was no effusion and thus the absence of effusion and absence of pain was found in 50% of total 30TMJ's. Presence of pain and presence of effusion was seen only in one TMJ of the 30 that makes 3.3% of 100% TMJ's imaged.

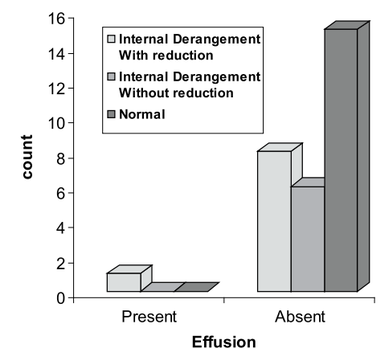

MRI findings of effusion in TMJ pain side

MRI findings of DD and MRI findings of effusion in patients with unilateral TMJ pain- Out of 30 TMJ's DD with reduction was seen in 09 TMJ's of which 1 had TMJ effusion where as rest 08 TMJ had no effusion. DD without reduction was seen in 06 TMJ's and none of these had effusion.

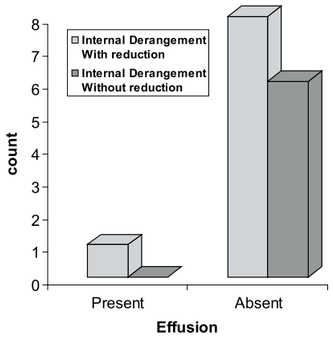

Relationship between TMJ pain (assessed by VAS) and MRI findings of DD - There were 9 joints with reduction and 6 with out reduction. The mean pain in patients with reduction was 5.11 where as in with out reduction was 4.67. The P was 0.563 thus making the relationship between TMJ pain and MR findings of type of DD insignificant.

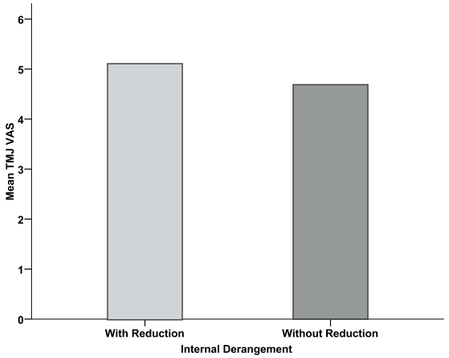

Graph assessing the relationship between TMJ pain (VAS scale) and MRI findings of DD

DISCUSSION

This study was done to assess the position of disc and presence of effusion in patients having unilateral TMJ pain. This study also assessed if there was any relationship between the presence of TMJ pain with TMJ DD and TMJ effusion using MR imaging diagnosis. In the present study, it was noted that significant amount of female patients were affected by TMD than males. Patients affected by TMD in this study group ranged from 16-30 years. Studies conducted by Rudi TE et al (1990),[6] Warren MP et al [7] and Nekora Azak K [8] have shown a similar prevalence.

In our study, all the TMJs associated with pain had DD and those which are taken as control had no evidence of DD. This observation compares favorably with the results of Roberto ES et al, [9] Tallents RH et al ,[10] Emshoff R et al, [11] RuDisch A et al [2], Emshoff R et al [12] and Kobs G et al.[13] But studies by Muller-Leisse C et al ,[14] Louis TK et al [15] and Bertram S et al [16] showed the presence of DD even in asymptomatic patients with no joint pain.

The frequency of anteriorly placed disc in the TMJ pain side was much higher (66.7%) than the presence of anteriolaterally placed disc (20%) and anteriomedially placed disc (13.4%). Louis TK et al [15] also stated that anterior DD is more common in both symptomatic as well as asymptomatic patients. Whyte AM et al [17] also came to the same conclusion as our study that anterior DD is common and anterolateral displacement was the second commonest type of displacement probably related to the weakness of the lateral disc attachment.

Presence of pain and presence of effusion was seen only in 3.3% of the whole population and only in 6.7% of those TMJ's had pain. Mukrami K et al,[18] Adame CG et al [19] and Guler N et al [20] also could not correlate TMJ pain and TMJ effusion. But Schellas KP et al, [21] Westesson PL et al, [3] Sano T et al, [22] Takahasi T et al,[23] and RuDisch A et al,[2] Larheim TA et al,[24] Emshoff R et al [25] found that TMJ pain had a high association with TMJ effusion.

The presence of effusion was seen in association with DD with reduction and was absent in DD without reduction. This is in contrast to the studies conducted by Yamamoto M et al,[26] Larheim TA et al [27] and Manfredini D et al.[28] They reported that joint effusion is likely to appear in painful TMJ's having DD without reduction. Adame CG et al [19] could find no such differences in effusion between the two groups of DD with reduction and DD without reduction.

The TMJ's belonging to the control group did not have any DD or effusion. Badel T et al,[29] Muller-Leisse et al,[14] Louis TK et al [15] and Bertram S et al [16] found DD in asymptomatic joints.

Bertram S et al [16] reported a prevalence percentage of 69.5% to 100.0 % pain in TMJ having DD with reduction and prevalence percentage of 47.5% to 100.0 % pain for TMJ DD without reduction. These findings support the concept that TMJ DD is involved significantly in the production of TMJ pain and dysfunction and this was in agreement with our study as all the 15 TMJ's having pain was found to be associated with MRI diagnosis of DD. But the severity of pain did not differ based on the type of DD in our study.

CONCLUSION

In the present study MRI of the TMJ was taken to assess the association between DD and effusion to joint pain. Displacement in the position of disc on the pain side was noted with no displacement in the control side. The frequency of anteriorly placed disc in the TMJ pain side was much higher, followed by anteriolateral and anteriomedial displacements respectively. Presence of effusion was seen in only one out of the 30 joints imaged and this was in a painful joint which had DD with reduction. Also further analysis showed that there was no significant relationship between TMJ pain and DD with reduction and without reduction.

Thus based on the present study an assumption can be made that painful TMJ is associated with a displaced disc but not necessarily with the presence of effusion. Also the intensity of pain does not differ much based on the position of disc or presence of effusion.

REFERENCES

1. McNeill C. Management of temporomandibular disorders: concepts and controversies. Journal of Prosthetic Dentistry 1997;77:510-22.
2. RuDisch A, Innerhofer K, Betram S, Emshoff R. Magnetic resonance imaging findings of internal derangement and effusion in patients with unilateral TMJ pain. Oral Surgery, Oral Medicine, Oral Pathology, Oral Radiology Endodontics 2001;92:566-71.
3. Westesson PL, Brooks SL. Temporomandibular Joint: Relationship Between MR Evidence of Effusion and the Presence of Pain and Disc Displacement. American Journal of Roententology 1992 September; 159:559-63
4. Haley DP, Schiffman EL, Lindgren BR, Anderson Q, Andreasen K. The relationship between clinical and MRI findings in patients with unilateral Temporomandibular joint pain. J Am Dent Assoc 2001;132:476-81
5. Schmitter M, Gabbert O, Ohlmann B, Hassel A, Wolff D, Rammelsberg P, et al. Assessment of the reliability and validity of panoramic imaging for assessment of mandibular condyle morphology using both MRI and clinical examination as the gold standard. Oral Surgery, Oral Medicine, Oral Pathology, Oral Radiology Endodontology 2001;102(2):220-4.
6. Rudy TE, Turk DC, Berna SF. Quantification of biomedical findings of chronic pain patients: development of an index of pathology. Pain 1990;42:167-82
7. Warren MP, Fried JL Temporomandibular disorders and hormones in women. Cells Tissues Organs 2001;169:187-92
8. Nekora-Azak K. Temporomandibular disorders in relation to female reproductive hormones: a literature review J Prosthet. Dent. 2004;91:491-3
9. Roberto ES, Ross HT, Richard WK, Jeffrey AG, Rochester NY.Bilateral internal derangement of temporomandibular joint: Evaluation by magnetic resonance imaging. Oral Surg Oral Med Oral Pathol. 1988; 65:281-5.
10. Tallents RH, Katzberg RW, Murphy W, Proskin H. Magnetic resonance imaging findings in asymptomatic volunteers and symptomatic patients with temporomandibular disorders. J Prosthet Dent. 1996 May; 75(5):529-33
11. Emshoff R, Innerhofer K, RuDisch A, Bertram S. Relationship between temporomandibular joint pain and magnetic resonance imaging findings of internal derangement. Int J Oral Maxillofac Surg. 2001 Apr;30(2):118-22.
12. Kobs G, Bernhardt O, Kocher T, Meyer G.

Critical Assessment of Temporomandibular Joint Clicking in Diagnosing Anterior Disc Displacement. Baltic Dental and Maxillofacial Journal 2005;7:28-30.

13. Muller-Leisse C, Augthun M, Roth A, Bauer W, Gunther RW. Disc displacement of the temporomandibular joint: correlation of magnetic resonance tomography and clinical findings. Rofo. 1996 Sep; 165(3):264-9

14. Muller-Leisse C, Augthun M, Roth A, Bauer W, Gunther RW. Disc displacement of the temporomandibular joint: correlation of magnetic resonance tomography and clinical findings. Rofo. 1996 Sep; 165(3):264-9

15. Louis TK, Douglas AO, Alexander SM, Mitsuaki A. Magnetic Resonance Imaging of the TMJ Disc in Asymptomatic volunteers. J Oral Maxillofac Surg. 1987;45:852-4.

16. Bertram S, RuDisch A, Innerhofer K, Pumpel E, Grubwieser G, Emshoff R. Diagnosing TMJ internal derangement and osteoarthritis with magnetic resonance imaging. J Am Dent Assoc. 2001 Jun; 132(6):753-61

17. Whyte AM, McNamara D, Rosenberg I, Whyte AW. Magnetic resonance imaging in the evaluation of temporomandibular joint Disc displacement-a review of 144 cases. Int J Oral Maxillofac Surg. 2006 Aug; 35(8):696-703

18. Murakami K, Nishida K, Bessho T. MRI evidence of high signal intensity and temporomandibular arthralgia and relating pain: Does the high signal correlate to the pain? Br J Oral Maxillofac Surg 1996;34:220

19. Adame CG, Monje F, Offnoz M Martin-Granizo R Effusion in magnetic resonance imaging of the temporomandibular joint: a study of 123 joints J Oral Maxillofac Surg 1998 Mar; 56(3):314-8.

20. Guler N, Uckan S, Imirzalıoglu P, Acıkgozoglu S Temporomandibular joint internal derangement: relationship between joint pain andMR grading of effusion and total protein concentration in the joint fluid. Dentomaxillofacial Radiology 2005;34:175-81.

21. Schellas KP, Wilkes CH.Temporomandibular joint inflammation: comparison of MR fast scanning with T1 and T2 weighted imaging techniques. Am J Roentgenol 1989;153:93-8.

22. Sano T, Westesson PL. Magnetic resonance imaging of the temporomandibular joint. Increased T2 signal in the retroDiscal tissue of painful joints. Oral Surg Oral Med Oral Pathol Oral Radiol Endod. 1995 Apr; 79(4):511-6.

23. Takahashi T, Nagai H, Seki H, Fukuda M. Relationship between joint effusion, joint pain, and protein levels in joint lavage fluid of patients with internal derangement and osteoarthritis of the temporomandibular joint. J Oral Maxillofac Surg. 1999 Oct; 57(10):1187-93.

24. Larheim TA, Westesson P ,SanoT. MR grading of temporomandibular joint fluid: association with Disc displacement categories, condyle marrow abnormalities and pain International Journal of Oral and Maxillofacial Surgery 2001 Apr; 30(2):104-12.

25. Emshoff R, Brandlmaier I, Bertram S, RuDisch A. Risk factors for temporomandibular joint pain in patients with Disc displacement without reduction - a magnetic resonance imaging study. J Oral Rehabil. 2003 May; 30(5):537-43.

26. Yamamoto M, Sano T, Okano T Magnetic resonance evidence of joint fluid with temporomandibular joint disorders. J Comput Assist Tomogr. 2003 Sep-Oct; 27(5):694-8.

27. Larheim TA. Role of magnetic resonance imaging in the clinical diagnosis of the temporomandibular joint. Cells Tissues Organs 2005; 180(1):6-21.

28. Manfredini D, Basso D, Arboretti R, Guarda-Nardini L.Association between magnetic resonance signs of temporomandibular joint effusion and Disc displacement .Oral Surg Oral Med Oral Pathol Oral Radiol Endod. 2009 Feb; 107(2):266-71.

29. Badel T, Marotti M, Keros J, Kern J, Krolo I. Magnetic resonance imaging study on temporomandibular joint morphology. Coll Antropol. 2009 Jun; 33(2):455-60.

ORIGINAL RESEARCH ARTICLE

KNOWLEDGE, ATTITUDE AND PRACTICE REGARDING UNIVERSAL PRECAUTIONS AMONG NURSING STUDENTS IN DAVANGERE CITY, KARNATAKA, INDIA- A CROSS SECTIONAL STUDY.

Authors:
Pooja Latti[1], Simpy Mittal[2], Prashant GM[3], Chandu GN[4], Girish Chour[5]

[1]Senior Lecturer, Department of Public Health Dentistry, PMNM Dental College and Hospital, Bagalkot, 587 101 Karnataka, India.

[2]Senior Lecturer, Department of Public Health Dentistry, Dr. D. Y. Patil Dental College and Hospital, Pimpri, Pune, Maharashtra, India.

[3]Reader, Department of Preventive and Community Dentistry, College of Dental Sciences, Pavilion Road, Davangere 577 004, Karnataka, India.

[4]Professor, Department of Preventive and Community Dentistry, College of Dental Sciences, Pavilion Road, Davangere 577 004, Karnataka, India.

[5]Senior Lecturer, Department of Oral and Maxillofacial Surgery, PMNM Dental College and Hospital, Bagalkot, Karnataka, India.

Address for correspondence: Dr. Pooja Latti, Senior Lecturer, Department of Public Health Dentistry, PMNM Dental College and Hospital, Bagalkot, 587 101 Karnataka, India. E mail: drpooja_l@yahoo.co.in.

ABSTRACT

Background: The new wave of nosocomial infections arising from various medical settings as well as other related environment has been of much concern for some time. The fact that blood and other fluids from patients are becoming increasingly hazardous to those who provide care for them had become of great concern to public health professionals the world over. This study was conducted to assess the knowledge, attitude and practice of universal precautions by nursing students in Davangere city, Karnataka, India.

Methodology: A total of 300 students studying in two Nursing Colleges of Davangere city were included in the questionnaire based survey. Among 300 nursing students, 231 were females and 69 were males.

Results: Out of the 300 respondents, 78.7% respondents claimed knowledge about universal precautions. 54.3% reported classroom lectures and 18.7% said personal reading of books/journals as their source of knowledge. Less than 50% wore aprons, face mask and gloves while examining all patients. Over 90% of the students felt that a nursing student needs more education about universal precautions.

Conclusion: The study revealed a low level of awareness regarding the universal precautions. Continuing educational programs and lectures directed towards universal precautions are highly recommended to increase the awareness and provide updated information on the same.

Keywords: Universal Precautions, Health Care Workers, Blood Borne Infections, Knowledge, Practice.

J Odontol Res 2013;1(2):7-11

INTRODUCTION

The new wave of nosocomial infections arising from various medical settings as well as other related environment has been of much concern for some time. The fact that blood and other fluids from patients are becoming increasingly hazardous to those who provide care for them had become of great concern to public health professionals the world over.[1]

It has specifically necessitated the need for a preventive approach in protecting care providers from such infections particularly from their patients. Thus the practice of universal precautions as a way of safeguarding possible routine infections in work places had become more and more a widely accepted among various health workers.[1]

It was in 1983, that the Centre for Disease Control (CDC) first published a document entitled Guideline for Isolation Precautions in Hospitals[2-4] that contained a section entitled "Blood and Body Fluid Precautions". The recommendations in this section called for blood and body fluid precautions when a patient was known or suspected to be infected with blood borne pathogens. In August 1987, CDC published another document entitled Recommendations for Prevention of HIV Transmission in Health-Care Settings[3-7]. In contrast to the 1983 document, the 1987 document recommended that blood and body fluid precautions be consistently used for all patients regardless of their blood borne infection status. This extension of blood and body fluid precautions to all patients is referred to as "Universal Blood and Body Fluid Precautions" or "Universal Precautions."[1,8,9] Under universal precautions, blood and certain body fluids of all patients are considered potentially infectious for human immunodeficiency virus (HIV), hepatitis B virus (HBV) and other blood borne pathogens.[1,8,9]

The term Universal Basic Precautions (UBP) was introduced in 1985 by Garner[10]. He defined it as: "the prevention of transmission of blood borne pathogens like HIV through strict respect by health workers of rules concerning care and nursing". Gerberding et al.[11] also defined Universal precaution: "the routine use of appropriate barrier and techniques to reduce the likelihood of exposure to blood, other body fluids and tissues that may contain blood borne pathogens".[12]

Universal precautions, as defined by CDC, are set of precautions designed to prevent transmission of Human Immunodeficiency Virus (HIV), Hepatitis B Virus (HBV) and other blood borne pathogens when providing first aid or health care.[13] This applies to blood and to other body fluids containing visible blood[14, 15] and also to vaginal secretions and semen.[1]

Universal precautions are intended to prevent parenteral, mucous membrane and non-intact skin exposures of health-care workers to blood borne pathogens.[1]

Universal precaution awareness education has not been pronounced among health care providers especially in developing countries. Graduating / qualifying medical and nursing students are important group of health care providers in that apart from the fact that they will upon graduation provide additional support to healthcare, they are also expected to inject new ideas to their practice all of which is expected to bring improvement to the service. It is therefore important to have information as regards what probable impact they are likely to have upon service provision as well as public health safety.[1]

With this context, this study was conducted with the aim of determining the level of knowledge, attitude and practice of nursing students with regards to universal precautions.

Methodology

The study was a cross-sectional questionnaire based survey. The target population was the nursing students (undergraduate students) who were randomly selected from the two nursing colleges of Davangere city. All the students present on the day of the survey were included. A total of 300 students participated in the study. Prior to the survey, the permission was obtained from the principals of the respective colleges and programmes were scheduled accordingly. The nursing students were approached directly by two post graduate students from the Department of Preventive and Community Dentistry, College of Dental Sciences, Davangere. A prefabricated validity tested questionnaire in English language was administered to the target population by the researchers and the students were asked to complete the questionnaires in the presence of the researchers.

Questionnaire

The questionnaire was divided into two parts. The first part consisted of questions on personal and professional information including age, gender and qualification. The second part of the questionnaire contained 19 questions which assessed the knowledge, attitudes and practice regarding universal precautions. All the questions were close-ended.

Ethical considerations

Ethical approval was obtained from the ethical committee of College of Dental Sciences, Davangere.

Statistical analysis

All returned questionnaires were coded and analyzed. Results were expressed as a number and percentage of respondents for each question and were analyzed using the SPSS Version 17 software. Chi square test was used to know whether there was any statistically significant difference between males and females. The level of significance was set at $p = 0.05$.

RESULTS

Among 300 nursing students, 77% (n=231) were females and 23% (n=69) were males. The students were aged between 17 to 23 years. No statistically significant differences were found between the two genders with respect to their responses to the various questions respectively.

The results obtained have been summarized and tabulated. The table shows the response to knowledge, attitude and practice based questions on universal precautions.

Table I: Response to the knowledge, attitude and practice based questions on universal precautions.

Question	Response	Percentage
1. Are u familiar with the concept of universal precautions?	Yes / No	78.7% 21.3%
2. Source of knowledge about universal precautions:		
❖ Class room lectures		54.3%
❖ Personal reading of books & journals		18.7%
❖ Seminars/workshops		12.0%
❖ Others sources		15.0%
3. Wearing of gloves during patient examination	Always / Occasionally	46.7% / 53.3%
4. Wearing of face masks	Always / Occasionally	31.7% / 68.3%
5. Wearing of aprons	Always / Occasionally	87.3% / 12.7%
6. Do you wash your hands after removing gloves?	Always / Occasionally	97% / 3%
7. Have you ever had a needle stick injury?	Yes / No	30% / 70%
8. Do you recap needles after use?	Yes / No	77.7% / 22.3%
9. Awareness regarding method of gloving in special cases.	Yes / No	65% / 35%
10. Should needles be recapped after use?	Yes / No	77.7% / 22.3%
11. Are you interested in participating in training programs regarding universal precautions?	Yes / No	91% / 9%

DISCUSSION

Out of the 300 respondents, 78.7% (n=236) respondents claimed knowledge about universal precautions and the remaining said that they are not familiar with the concept of universal precautions. When asked about their source of knowledge about universal precautions, 54.3% (n = 163) responded classroom lectures, 18.7% (n= 56) said personal reading of books/journals and the remaining claimed other sources. Hence, it was clear that the theoretical aspects of the nursing students overlooked the importance of incorporating the concept of universal precautions into classroom lectures and other related activities. These findings are similar to a study conducted by Bamigboye et al. [1] in 2006 in Nigeria.

While over 90 % of the respondents agreed that face mask, gloves and protective clothing should be worn while examining all patients and in practice less than 50% followed these universal precautions. Similar findings were reported in studies conducted by Bamigboye et al. [1] in 2006 and Askarian et al. [16] in 2007. The level of personal hygiene and related practices seemed to be low among the respondents. [1]

A high 93% (n = 279) of respondents observed hand washing after handling patients. This finding was similar to a study conducted by Sadoh W. E. et al. [17] in 2006. Hand washing practices after exposure of hands to possible sources of contamination has been known to be a major precautionary measure against many communicable diseases. [1]

Out of the 300 respondents, 30% (n=90) gave a history of needle stick injuries in their practice, of whom, 79 (n=87.8%) admitted that they did not report the incident to the hospital authority. These findings correspond to a study conducted by Gurubacharya et al. [18] in 2003 in Nepal wherein, 79% of the respondents never reported the incident of needle stick injury.

The recapping of needles has been prohibited under the Occupational Safety and Health Administration (OSHA) blood-borne pathogen standard. [18,19] In our study, 77.7% (n= 233) of the respondents were of the opinion that the needle must be recapped after use. This finding was similar to studies conducted by Gurubacharya et al. [18] in 2003 and Janjua et al. [20] in 2007. The circumstances leading to needle-stick injury depend partly on the type and design of the device and certain work practices. [18] It is documented that 10%-25% injuries occurred while recapping a used needles. [18,21]

Ninety one percent of the students (n = 274) felt that a nursing student needs more education about universal precautions and were willing to participate in a network to promote the knowledge, attitude and practice of universal precautions.

This study was limited by the self-report method of assessment of practice of universal precautions, because the level of compliance might have been more properly assessed by observation. The likely tendency for the respondents to exaggerate their compliance with universal precautions may have produced a less unfavorable picture than it actually is. [17]

CONCLUSION

The present study determined the level of knowledge, attitude and practice of nursing students with regards to universal precautions. The study revealed a low level of awareness regarding the universal precautions. Except for hand washing, personal hygiene and related practices seemed to be low among the respondents. The observation that the theoretical aspects of the nursing students overlooked the importance of incorporating the concept of universal precautions into classroom lectures dictates an urgent need to stress the importance of incorporating the teaching of universal precautions in classroom activities and related settings. Furthermore, continuing educational programs and lectures directed towards universal precautions with specific mention on biomedical waste disposal and post exposure prophylaxis are highly recommended to increase the awareness and provide updated information on the same, so as to ensure their safety when in professional practice in future.

REFERENCES

1. Bamigboye, Abiodun P., Adesanya, Abidemi T. Knowledge and Practice of Universal Precautions among Qualifying Medical and NursingStudents: A Case of Obafemi Awolowo University Teaching Hospitals Complex, ILE-IFE. Res J Med Med Sci 2006; 1(3):112-6.
2. CDC., 1982. Acquired immunodeficiency syndrome (AIDS): Precautions for clinical and laboratory staffs. MMWR., 31:577-80.3.
3. CDC.,1985. Recommendationsfor Protection against viral hepatitis MMWR., 34:313-324.
4. CDC., 1985. Recommendations for preventing transmission of infectionwithhuman T-lymphotropic virus type III lymphadenopathy-associated virus in the workplace. MMWR., 34:681-6,691-5.
5. McCarthy Gillian M., 2000. Universal Precautions. Jnl. Canadian Dental Association, 66:556-7.
6. CDC., 1987. Update: Human Immuno Deficiency Virus Infection in health care workers exposed to blood of infected patient. MMWR., 36:285-9.
7. CDC., 1986. Recommendations for preventing transmission of infection with human T-lymphotropic virus type III/lymphadenopathy-associated virus during invasive procedures. MMWR., 35:221-3.
8. CDC., 1988. Perspectives in Disease Prevention and Health Promotion Update: Universal Precautions for Prevention of Transmission of Human Immunodeficiency Virus, Hepatitis B Virus, and Other Bloodborne Pathogens in Health-Care Settings. MMWR., 37:377-88.
9. Biosafety in the laboratory- prudent practices for the handling and disposal of infectious materials. National Academy Press. Washington D.C. 1989:169.
10. Garner JB. What is in a name? Today's Surgical Nurse 1997;19(1):14-21,46-7.
11. Gerberding JL, Lewis FR, Schecter WP. Are Universal Precautions realistic? Surg Clin of North America 1995;75(6):1091-104.
12. Hesse A A J, Adu-Aryee N A, Entsua-Mensah K, Wu L. Knowledge, attitude and practice universal basic precautions by medical personnel in a teaching hospital. Ghana Medical Journal 2006;40(2):61-4.
13. CDC., Fact sheet. Updated 1996. Universal Precautions for Prevention of Transmission of HIV and Other Bloodborne Infections. www.cdc.gov/ncidod/dhqp/bp_universal_precautions.html.
14. CDC., 1983. Acquired immunodeficiency syndrome (AIDS): Precautions for health- care workers and allied professionals. MMWR., 32:450-1.
15. CDC., 1985. Recommendations for preventing possible transmission of human T-lymphotropic virus type III/lymphadenopathy-associated virus from tears. MMWR.,4:533-4.
16. Askarian M, Memish Z A, Khan A A. Knowledge, Practice, and Attitude Among Iranian Nurses, Midwives, and Students Regarding Standard Isolation Precautions. Infect Control Hosp Epidemiol 2007;28:241-4.
17. Sadoh W E, Fawole A O, Sadoh A E, Oladimeji A O, Sotiloye O S. Practice of Universal Precautions among Healthcare Workers.J Natl Med Assoc. 2006;98:722-6.
18. Gurubacharya DL, Mathura KC, Karki D. Knowledge, attitude and practices among health care workers on needle-stick injuries. Kathmandu University Medical Journal (2003);1(2):91-4.
19. Occupational safety and Health Administration: final rule on occupational exposure to blood borne pathogens. 56 Fed Reg. 64004(1991).
20. Janjua N Z, Razaq M, Chandir S, Rozi1 S, Mahmood B. Poor knowledge - predictor of nonadherence to universal precautions for blood borne pathogens at first level care facilities in Pakistan. BMC Infectious Diseases 2007,7:81.
21. Ruben FL, Norden CW, Rockwell K, Hruska. Epidemiology of accidental needle puncture wounds in hospital workers. Am J Ed Sci 1983;286:26-30.

ORIGINAL RESEARCH ARTICLE

A COMPARATIVE EVALUATION OF EASY REMOVAL OF DENTAL CASTS FROM ALGINATE IMPRESSIONS USING DIFFERENT BRANDS OF DENTAL STONE - AN IN VITRO STUDY

Authors:
AV Pius[1],
Seema George[2],
Meenu Merry C. Paul[3],
Sanju John Jolly[2],
Cinil Mathew[4],
Prasant P.S[5]

[1]Professor, Dept. of Prosthodontics,
Indira Gandhi Institute of Dental Sciences,
Nellikuzhy P. O., Kothamangalam 686 691,
Kerala, India.

[2]Reader, Dept. of Prosthodontics,
Indira Gandhi Institute of Dental Sciences,
Nellikuzhy P. O., Kothamangalam 686 691,
Kerala, India.

[3]Professor &HOD, Dept. of Prosthodontics,
Indira Gandhi Institute of Dental Sciences,
Nellikuzhy P. O., Kothamangalam 686 691,
Kerala, India.

[4]Senior Lecturer, Dept. of Prosthodontics,
Indira Gandhi Institute of Dental Sciences,
Nellikuzhy P. O., Kothamangalam 686 691,
Kerala, India.

[5]Reader, Dept. of Orthodontics,
Indira Gandhi Institute of Dental Sciences,
Nellikuzhy P. O., Kothamangalam 686 691,
Kerala, India.

Address for correspondence:
Dr. A. V. Pius, Professor,
Dept. of Prosthodontics,
Indira Gandhi institute of Dental sciences,
Nellikuzhy P. O., Kothamangalam 686 691,
Kerala, India.
E mail: drpiusav@yahoo.com.

ABSTRACT:

Background: The fracture of teeth on removal of dental stone models from an alginate impression is a common phenomenon. Fabrication of a restoration on a fractured prepared tooth leads to inaccuracies in the finished prosthesis. The objective of this study was to comparatively evaluate different brands of dental stone regarding easy removal of dental casts from alginate impressions.

Methodology: Three commercially available brands of dental stone were evaluated using three different tests namely static loading, continuous loading using electronic digital luggage scale, and intermittent loading using a crown remover, and the load applied was recorded.

Results: A significant difference existed among all the three different brands of dental stone in the various tests conducted. Among the three dental stones, the dental stone that contained the modifier exhibited the least values in the static loading test (20.5±2.14 kgs), Electronic Luggage Scale test (24±0.56 kgs) and Intermittent loading using crown remover (21.7±0.97 strokes).

Conclusion: In all the three tests one of the dental stone brands which contains a modifier required less load to be removed from the alginate impression.

Keywords: Dental stone, alginate impression

J Odontol Res 2013;1(2):12-6

INTRODUCTION

Removal of dental stone models from the alginate impression without fracture of teeth or casts is still a challenge to the dentist and dental technician. Fracture of prepared teeth leads to a distorted restoration and an ill-fitting prosthesis[1]. Some manufacturers of dental stone claim that with addition of certain modifiers to the dental stone, removal of dental stone from alginate impressions becomes easier. Hence, with this background, a study was conducted to compare the ease of removal of casts prepared with different brands of commercially available dental stone, from alginate impression.

Materials and Methods

Three commercially available brands of dental stone were tested for the ease of removal from alginate impression. The brands were:

A. Goldstone® from Asian Chemicals, Rajkot, Gujarat
B. Dentstone® from Pankaj Enterprises, Jammu
C. Eurostone® from Eurosiskenchemtech

The study was conducted in the Department of Prosthodontics, Indira Gandhi Institute of Dental Sciences, Nellikuzhi, Kothamangalam, Kerala. Ethical clearance for the conduct of study was obtained from the ethical committee of the institution.

Methodology:

A U3 size perforated impression tray was specially modified for the test. Three uniform sized metal hooks were welded to the upper surface of the tray. An alginate impression from a master model using tropicalgin was made using this tray. Dental stone was mixed using pre-measured water and pre-weighed stone powder as per manufacturer's guidelines, and poured in the impression placing on a vibrator. A metal hook was placed in the middle of the setting stone cast and it was allowed to set for 2 hours. The tray was then hooked on to an iron rod cemented to the wall. The impression and stone casts were then subjected to 3 different types of tests:-

1. Static loading
2. Continuous loading using a digital electronic luggage scale
3. Intermittent loading using a crown remover

1. Static loading: The entire apparatus was hung on to the iron rod using the three metal hooks on the tray. A load of 5 kilogram was applied initially for a period of 5 seconds. The load was gradually increased till the cast was dislodged from the impression. The load required to dislodge the impression was recorded in Table 1. Twenty such samples were tested.

Fig1: Figure showing static loading test

2. Continuous load by digital electronic luggage scale.

Using an electronic luggage scale (Camry, ISO 9001:2008, Model EL10) the stone cast was pulled down from the impression and the load was recorded on the electronic digital scale. The values were recorded in Table 2. Twenty such samples were tested.

Fig 2: Figure showing load application by digital electronic luggage scale

3. Intermittent loading using crown remover

The similar type of samples and apparatus were subjected to a load applied by intermittent loading using a crown remover. The crown remover used was of the pneumatic type (Automatic crown remover, marketed by Ashoo sons, Delhi). The number of strokes for removal of cast from the impression were counted and recorded in Table 3. Twenty such samples were tested.

Fig 3: Figure showing intermittent loading using crown remover

Statistical Analysis:

The results were summarised and tabulated in terms of mean± standard deviation in Table 4. Inferential analysis for evaluating significant differences (if any) between the various products in this study was done using one way Analysis of Variance followed by Tukey's post hoc test for pair wise comparison. The analysis was done using statistical package for social sciences (SPSS) version 17.0 for windows. The level of significance was set for α=0.05.

RESULTS

20 samples were tested for each brand of dental stone. The results obtained were tabulated as Table 1,2,3 and 4:

Table1: Table showing load applied in static loading test

Sample	Eurostone® (kilogram)	Goldstone® (kilogram)	Dentstone® (kilogram)
1	20	26	27
2	19	27	27
3	20	25	28
4	20	26	28
5	20	26	26
6	19	26	26
7	21	26	27
8	19	26	27
9	21	27	27
10	20	25	27
11	20	28	27
12	20	24	27
13	21	25	27
14	18	25	27
15	20	25	27
16	20	25	27
17	20	25	27
18	20	28	27
19	21	24	28
20	21	24	26
Average	20	26.95	27

Table 1 presents the load applied in the static loading test for all the three different brands of dental stone. Eurostone® needed an average of only 20kilogram, Goldstone® needed an average of 26.95 kilogram and Dentstone® an average of 27 kilogram to dislodge from the alginate impression.

Table2: Table showing load applied by digital electronic luggage scale

Sample	Eurostone® (kilogram)	Goldstone® (kilogram)	Dentstone® (kilogram)
1	24	30	32
2	24	31	33
3	24	32	31
4	24	30	30
5	24	29	31
6	23	29	31
7	24	30	32
8	25	29	32
9	24	30	33
10	24	29	33
11	23	31	31
12	25	29	32
13	25	31	31
14	23	30	32
15	24	30	31
16	24	31	32
17	24	31	31
18	24	30	32
19	24	29	32
20	24	30	32
Average	24	30.05	31.7

Table 2 presents the load applied by a digital electronic luggage scale to remove the dental stone cast from the alginate impression. Eurostone® showed an average of 24 kilograms, Goldstone® an average of 30.05 kilograms and Dentstone® an average of 31.7 kilogram.

Table 3: Table showing number of strokes in test using crown remover

Sample	Eurostone®	Goldstone®	Dentstone®
1	22	28	29
2	22	28	29
3	21	27	28
4	23	29	30
5	22	28	28
6	22	29	30
7	23	28	29
8	21	27	29
9	22	28	29
10	22	27	29
11	21	28	30
12	23	29	29
13	20	28	29
14	21	29	29
15	22	27	30
16	22	28	28
17	22	28	28
18	20	28	28
19	23	28	28
20	20	28	28
Average	21.7	28	30.25

Table 3 presents the number of strokes applied by the crown remover to dislodge the cast from the impression. Eurostone® showed an average of only 21 strokes, Goldstone® an average of 28 strokes and Dentstone® an average of 30 strokes.

Table 4: Table showing summarised results

Test	Eurostone® (E)	Goldstone® (A)	Dentstone® (B)	ANOVA test	Tukey's post hoc test
Static loading(Kg)	20.5±2.140	25.65±1.182	27±0.562	F=112.196 p<0.01	B>A>E
Electronic luggage scale(kg)	24±0.562	30.05±0.887	31.7±0.801	F=112.196 p<0.01	B>A>E
Number of strokes	21.7±0.979	28.0±0.649	28.85±0.745	F=473.242 p<0.01	B>A>E

Both the Anova test and Tukey's post hoc test reveal that a statistically significant difference existed for all the three different brands of dental stone in the various tests conducted between Eurostone®, Goldstone® and Dentstone®.

The pair wise comparison revealed that Eurostone® needed the least force (kg) and crown remover strokes for removal of cast from alginate impression than the other two brands. Goldstone® needed the second least force and strokes and, Dentstone® needed the most force and strokes for removal of cast from alginate impression.

DISCUSSION

The objective of this study was to compare the three commercially available dental stones namely Goldstone®, Dentstone®, and Eurostone® in relation to the ease of removal of set dental stone from alginate impression material.

Eurostone® is a commercially available brand of dental stone that claims to have modifiers that ease the removal of set stone from the impression. Hence Eurostone® was included in the study.

The results of this study show that casts poured using Eurostone® are more easily detachable from the alginate impression than casts poured from the other two brands of commercially available dental stone. The detachability is probably contributed by the modifier in Eurostone®, which manufacturers claim acts as a lining or separating media on the cast surface.

Although studies have been done on other aspects of teeth fracture on casts, no study has been reported in the available electronic literature evaluating the ease of removal of dental stone casts from alginate impressions.

Von Krammer R. studied the methods of avoidance of cast breakage during removal from impression. Methods such as sectioning the impression tray were found to be effective[1]. But such methods are time consuming and expensive. Likeman P and Paolinelis G investigated the accuracy of refixing broken teeth to stone casts using a Triclone contact scanner. They found that fractured teeth were significantly displaced from their original position, thereby affecting the accuracy of the fabricated prosthesis.[2]

The present study was conducted using alginate impression material. Galindo D and Hageman ME studied cast breakage during separation from elastomeric impressions. They felt the rigidity of the impression material is responsible for the fracture[3].Hence further studies are recommended using other impression materials like elastomeric impression materials.

The laboratory significance of this study is that the dental stone with such modifiers can be used without fear of cast fracture during separation from alginate impression material, thereby enabling fabrication of a successful prosthesis.

CONCLUSION

Eurostone® dental stone was found to be more easily detachable from the alginate impression material than Goldstone® and Dentstone®. Goldstone® was found to be more easily detachable from alginate impression than Dentstone® dental stone.

REFERENCES

1. Von Krammer R. Avoidance of cast breakage during removal from the impression. Quintessence Int.1990 Mar; 21(3):217-20
2. Likeman P, Paolinelis G. An investigation of the accuracy of refixing broken teeth to stone casts. Eur J Prosthodont Restor Dent. 2007 sep;15(3):127-30
3. Galindo D, Hagan M E. Procedure to prevent cast breakage during separation from elastomeric impressions. J Prosthet Dent. 1999Jan; 81(1):37-8

ORIGINAL RESEARCH ARTICLE

ANTIMICROBIAL ACTIVITY OF COMMERCIALLY AVAILABLE ESSENTIAL OILS AGAINST CANDIDA ALBICANS - AN IN VITRO STUDY

Authors:
Mahesh Kumar M.[1],
Prasanna Kumar R. K.[2],
Roopa Mahesh[2],
B. Karthikeyan[3]

[1]Assistant Professor,
Department of Community Dentistry, CSI Dental College and Research, Madurai 625 001, Tamil Nadu, India.

[2]Private practitioner
[3]Senior Lecturer,
Department of Periodontics, CSI Dental College and Research, Madurai 625 001, Tamil Nadu, India.

Address for correspondence:
Dr. Mahesh Kumar M.,
Assistant Professor,
Department of Community Dentistry,
CSI Dental College and Research,
Madurai 625 001, Tamil Nadu, India.
E mail: mahi_dr2002@yahoo.com.

ABSTRACT

Background: Many essential oils have been advocated for use in complementary medicine for bacterial and fungal infections. However few of the many claims of therapeutic efficacy have been validated adequately by either in vitro testing or in vivo clinical trials. The objective of the study was to study the antifungal activity of nine commercially available essential oils against Candida albicans in vitro and to compare the antifungal activity between each material.

Methodology: Nine pure essential oils; wintergreen oil, lime oil, cinnamon oil, spearmint oil, peppermint oil, lemongrass oil, cedarwood oil, clove oil and eucalyptus oil were selected for the study. Candida albicans was inoculated at 37°C and seeded on Sabourauds dextrose agar medium. Sterilized filter paper saturated with the oils were placed on the seeded agar plates and inoculated for 48 hours. Zone of inhibition were measured around the filter paper in millimeters with vernier caliper.

Results: Cinnamon oil showed highest activity against Candida albicans followed by Lemongrass oil and cedarwood oil. Wintergreen oil, lime oil, peppermint oil and spearmint oil showed no antifungal activity.

Conclusion: The use of these essential oils against Candida can be a viable alternative to other antifungal agents as these are an effective module used in the control of both bacteria and yeasts responsible for oral infections.

Key words: Candida albicans, anti fungal property, disc diffusion, essential oils.

J Odontol Res 2013;1(2):17-20

INTRODUCTION:

Many essential oils have been advocated for use in complementary medicine for bacterial and fungal infections including boils, acne, gingivitis and vaginal candidiasis. However few of the many claims of therapeutic efficacy have been validated adequately by either in vitro testing or in vivo clinical trials. Unless these claims have been substantiated scientifically, complementary medicines are unlikely to secure a place in conventional health care.[1]

The spread of drug resistant pathogens is one of the most serious threats to successful treatment of microbial diseases. Down the ages essential oils and other extracts of plants have evoked interest as sources of natural products. They have been screened for their potential use as alternative remedies for the treatment of many infectious diseases. World Health Organisation (WHO) noted that majority of the world's population depends on traditional medicine for primary care.

Medicinal and aromatic plants which are widely used as medicines, constitute a major source of natural organic compounds.

Essential oils have been shown to possess antibacterial, antifungal, antiviral, insecticides and antioxidant properties. Some oils have been used in cancer treatment. Some other oils have been used as food preservative, aroma therapy and fragrance industries. Essential oils are a rich source of biological active compounds.[2,3]

There has been an increased interest in looking at antimicrobial properties from extracts of aromatic plants particularly essential oils. Therefore it is reasonable to expect a variety of plant compounds, in their oils with specific as well as general antimicrobial activity and antibiotic potential. Essential oils (also called volatile oils) are aromatic oily liquids obtained from plant materials (flowers, buds, seeds, leaves, twigs, barks, herbs, wood, fruits and roots). An estimated 3000 essential oils are known, of which 300 are commercially important in fragrance market. Essential oils are complex mixtures comprising of many single compounds. Chemically they are derived from terpenes and their oxygenated compounds. Each of them constitutes and contributes to the beneficial or adverse effects.[2]

Hence this study was conducted with the objective of assessing the antifungal activity of nine commercially available essential oils against Candida albicans in vitro and to compare the antifungal activity of these materials.

MATERIALS AND METHODS:

Collection of materials: The following pure essential oils commercially available in Davangere city were selected for the study: wintergreen oil, lime oil, cinnamon oil, spearmint oil, peppermint oil, lemongrass oil, cedarwood oil, clove oil and eucalyptus oil. All oils were non diluted and chemically not altered by any solvent or processing. Pure cultures of Candida albicans were obtained from Department of Microbiology, Jagadguru Jayadeva Murugarajendra Medical College, Davangere.

Antimicrobial tests: The Disc diffusion method was used to determine the antimicrobial activity. A volume of tested microorganisms grown in Sabourauds dextrose agar (at 37°C for 24 hours), were inoculated on Sabourauds agar growth media, and then spread on the entire surface of the dish using a sterile cotton swab. Sterile paper disc, 6 mm. diameter with absorbed oil (30 µl /disc) was placed onto the agar at certain intervals by pressing gently. After the plates were incubated at 37±0.1°C for 48 hours, the inhibition zones around the discs where no growth occurred were measured on all four sides of the filter paper in millimeters using a vernier caliper. The experiments were repeated and ten readings were taken per essential oil used.

Statistical analysis:

The mean and standard deviation of the zones of inhibition around the discs were tabulated. Statistical significance was measured by using one way ANOVA followed by Tukey's post hoc test. p value <0.05 was considered statistically significant. The analysis of data was done by SPSS Version 16.0 (Statistical Package Software).

RESULTS:

Cinnamon oil showed highest activity against Candida albicans followed by Lemongrass oil and cedarwood oil. Eucalyptus oil showed the least antifungal activity. Wintergreen oil, lime oil, peppermint oil and spearmint oil showed no antifungal activity. The differences between each of the essential oils were significant at the end of 48 hours.

Table I; shows antifungal activity (zone of inhibition in millimeters) of the essential oils against C. albicans at 48 hours respectively.

Graph I; shows the differences in antifungal activity between the essential oils 48 hours.

DISCUSSION:

The essential oils that were used in this study were the ones commercially available in the local market. Four of the nine essential oils tested in this study demonstrated effective antifungal activity against C. albicans, of which cinnamon oil was found to be the most effective.

Numerous essential oils have been tested for in vivo and in vitro antifungal activity and some demonstrated to be potential antifungal agents. Their mechanism of action appears to be predominantly on the fungal cell membrane, disrupting its structure causing cell leakage and cell death; blocking the membrane synthesis; inhibition of the spore germination, fungal proliferation and cellular respiration. Because of high volatility and lipophilicity of the essential oils, they are readily attached to penetrate into the cell membrane and exert their biological effect.[3]

Usually ethanol is added to the essential oils as solvent to enhance the volatility and aromatic properties.[4] Thus to avoid the possible effect of the solvent on the antimicrobial property, commercially available essential oils that were non diluted and chemically not altered by any solvent or processing were used in this study.

According to this study, cinnamon oil was found to be the most effective against C. albicans. Numerous studies have shown similar results.[1,4,5,6,7] The antimicrobial activity of cinnamon may be explained by its volatile oil components. The most important active substance found in cinnamon oil are cinnamic aldehyde and eugenol.[6]

This study also demonstrated the anti fungal properties of lemongrass oil, cedarwood oil, clove oil and eucalyptus oil. The results obtained are comparable to various similar studies conducted.[3,4,5,6].

In the agar disc diffusion tests, the size of the effective inhibitory zone depends on the solubility and diffusion characteristics of the substances being tested. This makes the comparison of the different oils difficult. Therefore, the results of this study may not directly reflect the extent of the antifungal potential of these oils. However, as these effective zones were clearly visible, this is a proof of their antifungal efficacy.

Table I shows antifungal activity (zone of inhibition in millimeters) of the essential oils against C. albicans at 48 hours respectively.

Sl. No.	ESSENTIAL OIL	MEAN	STANDARD DEVIATION	ANOVA	TUKEY'S POST HOC
1	WINTER GREEN OIL	.00	.00	F value = 1294.07 p value = 0.001 (HS)	3>6>7>8>9 =1=2=4=5
2	LIME OIL	.00	.00		
3	CINNAMON OIL	12.11	.66		
4	SPEARMINT OIL	.00	.00		
5	PEPPERMINT OIL	.00	.00		
6	LEMON GRASS OIL	10.27	.71		
7	CEDAR WOOD OIL	7.62	.53		
8	CLOVE OIL	6.16	.49		
9	EUCALYPTUS OIL	3.94	.37		

Graph I: shows the differences in antifungal activity between the essential oils at 48 hours.

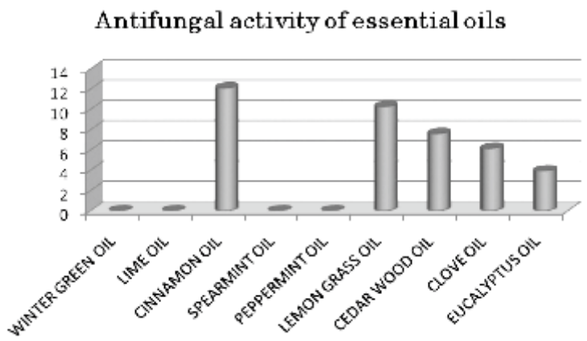

Studies have also been conducted to assess the anti-bacterial effectiveness of these essential oils against oral bacteria wherein all the oils used in the study have demonstrated varying amount of antibacterial effectiveness.[5,6,7,8]

Thus as some these essential oils have proved to have antimicrobial efficacy against oral bacteria and fungi in vitro, in vivo studies containing these oils are recommended so as to allow these essential oils to be incorporated within formulations marketed against oral infections.

CONCLUSION:

Cinnamon oil, lemongrass oil, cedarwood oil, clove oil and eucalyptus oil exhibit antifungal property against C. albicans. Thus the use of these essential oils against Candida can be a viable alternative to other antifungal agents as these offers an effective module used in the control of both bacteria and yeasts responsible for oral infections such as caries, periodontal disease and stomatitis.

REFERENCES:

1. Hammer KA, Carson CF, Riley TV. In vitro activity of essential oils, in particular Melaleuca alternifolia (tea tree) oil and tea tree oil products against Candida spp. Journal of Antimicrobial chemotherapy 1998;42:591-5.
2. Prabuseenivasan S, Jayakumar M, Ignacimuthu S. In vitro antibacterial activity of some plant essential oils. BMC Complementary and Altenative Medicine 2006;6:39.
3. Cristiane da silva, Gutteres SS, Weisheimer V, Schapoval EES. Antifungal activity of lemongrass oil and citral against candida spp. The Brazilian journal of Infectious Diseases 2008;12(1):63-66.
4. Agaoglu S, Dostbil N, Alemdar S. Antimicrobial activity of some spices used in the meat industry. Bull Vest Inst Pulawy 2007;51:53-57.
5. Abdel Mallek AY, Bagy MMK, Hasan HAH. The in vitro anti yeast activity of some essential oils. Journal of Islamic Academy of Sciences 1994;7(1):10-2.
6. Sattari M et. al. An inspection of antimicrobial activities of essential oils eucalyptus polycarpa, Eucalyptus largiflorence, Eucalyptus mallidora and Eucalyptus Camaldulensis on Staphylococcus aureus in the laboratory. Iranian journal of Pharmaceutical research. 2010;9(1).
7. Ott JA, Morris AN. Homeopathic alternatives to conventional antibiotics. BIOS 2008;79 (2): 50-5.
8. Pattnaik S, Padhan DK, Jana GK. Evaluation of cinnamon oil,peppermint oil, cardamom oil and orange oil as antimicrobial agents. Journal of Pharmacy research 2010; (2):414-6

ORIGINAL RESEARCH ARTICLE

'INDIVIDUAL VARIATION OF SALIVARY FACTORS AND ITS VARIATION IN RELATION TO DENTAL CARIES EXPERIENCE AMONG TWELVE YEAR OLD RESIDENTIAL SCHOOL CHILDREN IN DAVANGERE CITY'- A SIX MONTHS FOLLOW UP STUDY

Authors:
Subramaniam R[1], Simpy Mittal[2], Mahesh Hiregoudar[3], Sakeenabi B.[4], Prashant GM[4], Chandu GN[5]

[1]Senior Lecturer, Department of Public Health Dentistry, Indira Gandhi Institute of Dental Sciences, Nellikuzhy P. O. Kothamangalam 686 691, Kerala, India.

[2]Senior Lecturer, Department of Public Health Dentistry, Dr. D. Y. Patil Dental College and Hospital, Pimpri, Pune, Maharashtra, India.

[3]Senior Lecturer, Department of Public Health Dentistry, Coorg Institute of Dental Sciences, K. K. Campus, Magula, Virajpet 571 218, Karnataka, India.

[4]Reader, Department of Preventive and Community Dentistry, College of Dental Sciences, Pavilion Road, Davangere 577 004, Karnataka, India.

[5]Professor, Department of Preventive and Community Dentistry, College of Dental Sciences, Pavilion Road, Davangere 577 004, Karnataka, India.

Address for correspondence:
Dr. Subramaniam R., Senior Lecturer, Department of Public Health Dentistry, Indira Gandhi Institute of Dental Sciences, Nellikuzhy P. O. Kothamangalam 686 691, Kerala, India.
E mail: subbds@gmail.com.

ABSTRACT

Background: Salivary counts of Mutans Streptococci and Lactobacilli, combined with the measurement of salivary flow rate and buffer effect are frequently used for diagnostic and predictive purposes in cariology. The intra and inter individual variation is particularly important at the time of tooth emergence, which allows new tooth surfaces to become colonized. Thus there is a need of combination of diagnostic tests to target high risk caries groups. The purpose of the present study was to evaluate the variations in salivary factors (salivary flow rate, buffering capacity, Mutans streptococci counts and Lactobacilli counts) among children with different caries experience, to evaluate individual variations of salivary factors at different time intervals.

Methodology: A six month follow up study was conducted among ninety school children aged between 12 and 13 years, from a residential school in Davangere city. The study subjects were grouped according to their caries experience. Resting saliva was collected from the study subjects. Salivary flow rate was expressed in ml / min. Salivary buffering capacity was assessed using Ericsson's method modified for smaller volumes. Mutans Streptococci was quantified in the laboratory by culturing on Mitis Salivarius Bacitracin agar and Lactobacilli by culturing on Rogosa SL agar. Follow up samples were taken at 6, 12 and 24 weeks. Statistical analysis was done using Kruskal Wallis and Mann Whitney U tests.

Results: All the salivary factors studied showed significant relationship with caries experience. No significant variation was observed over a period of 24 weeks.

Conclusion: The study indicated that the salivary variables studied are a valuable diagnostic tool to assess caries experience and predict caries risk.

Key words: Caries; caries experience; flow rate; buffering capacity; Mutans streptococci; Lactobacilli.

J Odontol Res 2013;1(2):21-33

INTRODUCTION

Dental caries is a microbial disease of the calcified tissues of the teeth, characterized by demineralization of inorganic portion and destruction of organic substances of the tooth leading to cavity formation. Dental caries is a disease with a multifactorial aetiology, as it is due to the interaction of various factors: diet, the host's susceptibility and the presence of microorganisms over a certain length of time.

Among the oral diseases, dental caries is the most common chronic disease of mankind. It affects persons of both sexes in all races, all socio-economic strata and every age group. As children reach school age, they will have an increasing incidence of carious lesions because of change in dietary habits which includes refined carbohydrates and sweeteners. It is also profoundly affected by other factors like oral hygiene and saliva.[1]

The factors related to the development of dental caries are extremely relevant in the disease process. The microorganisms with cariogenic capacity do not determine the presence of dental caries. It is necessary to have suitable substrates and physiological conditions in the host to allow implantation and survival of these microorganisms in order to facilitate the development of caries. That is why caries is considered to be a multifactorial disease.[2]

Due to the multifactorial and complex etiology, unfortunately there is no single test available that can fully explain or predict the disease.[3] Salivary counts of Mutans streptococci and Lactobacilli, combined with the measurement of salivary flow rate and buffer effect are frequently used for diagnostic and predictive purposes in cariology. The variability of these tests on an individual level is not well documented. For the purpose of predicting and diagnosing dental caries, the intra and inter individual variation is particularly important at the time of tooth emergence, which allows new tooth surfaces to become colonized.[4]

Thus there is a need of combination of diagnostic tests to target high risk caries groups. The purpose of the present study was to evaluate the variations in salivary factors (salivary flow rate, buffering capacity, Mutans streptococci counts and Lactobacilli counts) among children with different caries experience, to evaluate individual variations of salivary factors at different time intervals.

METHODOLOGY

The present study is a six month follow up study conducted among ninety school children aged between 12 and 13 years, from a residential school in Davangere city, to evaluate the intra and inter individual variation in salivary factors in relation to their caries experience. Prior to the start of study, the study proposal was submitted for approval and clearance from the Ethical review board of College of Dental Sciences, Davangere. Permission to conduct the study was obtained from the school authorities of the residential school. A specially prepared and pretested format in English language, exclusively designed for recording all the relevant data pertaining to general information, salivary variables, and microbiological findings were used. Pilot study was conducted before the main study to check the feasibility and validity of the study. By standardizing all the materials and methods, the study was conducted by considering a total of 9 children, 3 in each group (caries free, medium caries, high caries). Pilot study assessments were utilized for proper planning and execution of the main study and also to finalize the procedure, method and analysis of the saliva samples. These 9 children who participated in the pilot study were not included in the main study. All the examinations and laboratory analysis were carried out by a single examiner (i.e., investigator himself) and recording was done by another person, who was familiar with the proforma. Sample size determination was based on the prevalence of Lactobacilli count in resting saliva among high caries risk patients, as observed in a previous study.[2] The sample size (n) was calculated from the following formula.

$$n = \frac{z^2pq}{d^2}$$

where,

z = 2 (assuming the distribution is normal and confidence limit is 95%)

p = the prevalence of Lactobacilli among high caries experience patients (in %) = 70

q = 1- p (in %) = 30

d = Admissible error in estimation = 15% of p (standardised) = 15% of 70 = 10.5

Substituting the values in the formula, the total number of samples is approximately 76 cases and when divided into three equal groups (based on dental caries experience), will give a sample size of approximately 25 subjects per group Based on the above calculations, to compensate for dropouts if any, a sample size of 30 subjects per group was used in this study thus totalling to 90 subjects. The study was conducted for a period of six months from 3rd August 2009 to 3rd February 2009 at Smt. Pushpa Shamnur Mahalingappa Residential School, a residential school located in Davangere city with strength of 300 students aged 12-13 years, was selected for the study. From this school, the children fulfilling all the inclusion and exclusion criteria were selected.

Inclusion criteria:

1. School children in age group of 12 years.

2. Minimum of 20 natural teeth.

Exclusion criteria:

1. Children with orthodontic appliances.

2. Recent antibiotic therapy

3. The presence of any systemic illness.

Those children who fulfilled the above criteria were screened for caries status using mouth mirror and explorer. Caries status of each child was scored by using DMFT index. They were assigned into three groups based on their DMFT scores (≥6 High risk, 1-5 Medium risk and <1 Caries free).[5] As per the sample size estimation, a total of 90 children were included in this study with 30 students in each group.

Written informed consent was obtained from the Principal of the residential school before the beginning of examination by discussing with them the purpose of the study, the advantages and the disadvantages associated with the study.

Collection of Saliva

On the day of collection, participating children were instructed not to eat or drink anything for at least one hour before the collection of saliva sample. To control the circadian variations, samples were collected between 8:00 am – 9:00 am. All necessary armamentarium required for saliva collection were assembled before the saliva collection procedure. Children were asked to rinse their mouth with water thoroughly 10 minutes before collection of saliva to avoid the contamination of food debris. Then they were made to sit on a chair. For collection of resting saliva, the children were instructed to let saliva collect in the floor of the mouth without swallowing it for atleast 1 min, and then to expectorate into the sterile graduated measuring cylinder with the help of a sterile funnel. This procedure was continued for a period of 5 minutes.

Estimation of salivary flow rate[6]

The flow rate of resting and stimulated saliva was determined by the following formula: Salivary flow rate = $\frac{\text{Total amount of saliva expectorated in 5 min (in ml)}}{5}$

Salivary flow rate was expressed in ml / min.

The salivary flow rate was determined and classified as follows

1: Very low < 0.1 ml/min.

2: Low: 0.1-0.25 ml/min.

3: Normal: 0.25-0.35 ml/min.

4: High: >0.35 ml/min.

Estimation of salivary buffering capacity

pH of saliva was measured by using manual pH meter. The estimation of buffering capacity was carried out as per the method described by Ericsson (1959) modified for smaller volumes[7].

Based on final pH of saliva

1: Low: < 4.1.

2: Intermediate: 4.1-5.5.

3: High: > 5.5.

Microbial analysis of saliva[8]

The saliva sample was homogenized manually by stirring using a stirrer. Hundred microliters of saliva was diluted with 1 ml of sterile peptone water to obtain 1:10 dilution of saliva. 100 µl of the diluted saliva

was further added to 1 ml. of sterile peptone water to obtain a dilution of 1:100. This procedure was repeated again to obtain a dilution of 1:1000. This dilution of saliva was used for microbial analysis.

Mutans streptococci were cultured on Mitis Salivarius Bacitracin agar and Lactobacilli on Rogosa SL agar, which are the selective media for culture of these organisms. The MSB agar plates were incubated for 48 hours at 37° C, anaerobically using candle jar. The Rogosa SL agar plates were incubated for 48 hours at 37°C, aerobically in the incubator. After 48 hours of incubation, the colonies were identified and counted using an electronic counter.

Based on Colony Forming Units (CFUs) per ml. of saliva

1: $<10^5$

2: $\geq 10^5$ - $<10^6$

3: $\geq 10^6$

Statistical analysis:

Data collected by experiments were computerized and analyzed using the Statistical Package for Social Sciences (SPSS) version 17.0.

Results were expressed in frequencies. Nonparametric tests namely Kruskal Wallis ANOVA test and Mann Whitney U test were used for testing the statistical significance.

Kruskal Wallis ANOVA test was used for comparison of salivary factors in relation to the caries experience groups and as well as comparison of salivary factors at various time intervals. The intra-group analysis in relation to caries experience groups and different time intervals were analysed using Mann Whitney U test.

The variation of salivary factors between males and females were analysed using Mann Whitney U test.

For all tests a p-value of 0.05 or less was considered for statistical significance.

RESULTS

This 24 week follow up study to assess the variation in salivary variables was conducted among 90 children, aged 12-13 years, studying in a residential school in Davangere city.

Table 1 shows the comparison of resting salivary flow rate amongst subjects with different caries experience at different time intervals. None of the subjects had a resting salivary flow rate of < 0.1ml/min. In caries free group, none of the subjects had low salivary flow rate (0.1 – 0.25 ml/min) and on the contrary, in high caries experience group, none of the subjects had a high flow rate (> 0.35 ml/min.). It was observed that there is a statistically significant difference in resting salivary flow rates in different caries experience group at all time intervals ($p<0.001$). The significance was observed between all the three groups. The subjects with no caries showed significantly high flow rate in comparison to caries active subjects ($p<0.001$). Significant difference also existed in flow rates among medium and low caries group at all time intervals ($p<0.001$).

Table 2 shows the comparison of resting salivary buffering capacity amongst subjects with different caries experience at different time intervals. It was observed that there was a statistically significant difference in resting salivary buffering capacities in different caries experience group at all time intervals. The subjects with no caries showed significantly high buffering capacity in comparison to subjects with medium and high caries risk. However there was no significant difference in buffering capacities among medium and low caries group at any of the time intervals.

Table 3 shows the comparison of resting salivary Mutans streptococci counts amongst subjects with different caries experience at different time intervals. It was observed that there was a statistically significant difference in resting salivary Mutans streptococci count amongst subjects with different caries risk at all time intervals. The subjects with high caries risk showed significantly high Mutans streptococci counts in comparison to subjects with medium risk and caries free subjects. There was also a significant difference in Mutans streptococci counts among medium and low caries group at all the time intervals. None of the caries free subjects had a high count of Mutans streptococci ($\geq 10^6$ CFU/ml). Only one subject of high caries group at baseline had a count of Mutans streptococci ($< 10^5$ CFU/ml).

Table 4 shows the comparison of resting salivary Lactobacilli counts amongst subjects with different caries experience at different time intervals. It was observed that there was a statistically significant difference in resting salivary Lactobacilli counts amongst subjects with different caries risk at all time intervals. The subjects with high caries risk showed significantly high Lactobacilli counts in comparison to subjects with medium risk and caries free subjects. There was also a significant difference in Lactobacilli counts among medium and low caries group at all the time intervals.

Table 5 shows the comparison of resting salivary flow rate among subjects with different caries risk at different time intervals. Table 6 shows the comparison of buffering capacity of resting saliva among subjects with different caries risk at different time intervals. Table 7 shows the comparison of Mutans streptococci counts in resting saliva among subjects with different caries risk at different time intervals. Table 8 shows the comparison of Lactobacilli count in resting saliva among subjects with different caries risk at different time intervals. It was observed that over a period of 24 weeks, none of the caries risk groups studied showed statistically significant difference in relation to any of the salivary variables assessed.

DISCUSSION

It is known that good oral health is an integral component of good general health. Although enjoying good oral health includes more than just having healthy teeth, many children have inadequate oral and general health because of active and uncontrolled dental caries. Dental caries is a disease process that afflicts a large proportion of the world's population. The etiology and pathogenesis of dental caries is multifactorial. Numerous host, agent and environmental factors play a role in the development of dental caries.[9]

Table 1: Comparison of resting salivary flow rate amongst subjects with different caries experience at different time intervals

CARIES EXPERIENCE		RESTING SALIVARY FLOW RATE AT DIFFERENT TIME INTERVALS															
		BASE LINE				6 WEEKS				12 WEEKS				24 WEEKS			
		1	2	3	4	1	2	3	4	1	2	3	4	1	2	3	4
HIGH		0	17	13	0	0	16	14	0	0	15	15	0	0	17	13	0
MEDIUM		0	1	27	2	0	0	28	2	0	0	28	2	0	0	27	3
FREE		0	0	4	26	0	0	4	26	0	0	1	29	0	0	3	27
Kruskal Wallis ANOVA	$\chi 2$	62.875				63.470				70.616				65.093			
	p value	0.001(HS)				0.001(HS)				0.001(HS)				0.001(HS)			
Mann Whitney U test		F>M (p<0.001) M>H (p<0.001) F>H (p=0.001)				F>M (p<0.001) M>H (p<0.001) F>H (p=0.001)				F>M (p<0.001) M>H (p<0.001) F>H (p=0.001)				F>M (p<0.001) M>H (p<0.001) F>H (p=0.001)			

HS – Highly significant, S – Significant, NS – Not significant
Caries Experience: H – High, M- Medium, F – Caries Free
Flow rate: 1= <0.1 ml/min., 2= 0.1-0.25 ml/min.,3=0.25-0.35 ml/min., 4= >0.35 ml/min.

The concept of the prediction of human dental caries risk has existed for many years. Salivary research has thus become an important field of dentistry and oral biology.[10]

Caries status of each child was scored using DMFT index. The age group of 12-13 years was selected for the study for the following reasons:

1. 12 years is one of the index age groups as recommended by the World Health Organisation.

2. It is the global monitoring age for international comparisons and monitoring of disease trends.[11,12]

3. It is one of the key ages or risk ages to be considered for caries risk assessment for screening in schools.[3]

Although various factors directly or indirectly affect the variables that are under study, diet appears to be one of the major factors that can have a profound influence on the variables. Strong evidence indicates that the association of Lactobacilli and Mutans streptococci with caries development is linked directly to carbohydrate consumption which, in turn, is one of the indispensable factors in caries development.[13] Hence a single residential school was selected for the study and for the same reason only students staying in the school hostel and not day-scholars were included as study samples. Under resting conditions without the exogenous stimulation associated with feeding, there is slow flow of saliva which keeps the mouth moist and lubricates the mucous membrane. This unstimulated flow, which is present majority of the time, is very important for the health and well being of the oral cavity and also imparts strong protective effect against dental caries.[14,15]

Several methods of collecting saliva are available. They are: draining method, spitting method, suction method and swab method. According to Navazesh and Christensen spitting method appeared to be most reproducible.[16] Hence this method of saliva collection was employed in this study.

In this study, it was observed that there was a statistically significant difference in resting salivary flow rates in all the three different caries experience groups. The results of this study are similar to the studies conducted by Hoolbrook et al in Iceland[17], Sawair et al in Jordan[18] and Gopinath et al in Malaysia[15]. However, huge amount of literature is available citing the association of xerostomia and increased dental caries prevalence that indicates the association between salivary flow rate and dental caries.[19]

There was no significant association between salivary flow rate and dental caries experience in studies reported by Parvinen T et. al in Hungary[20] and Bretz et. al. in Brazil[21]. However, according to Tenovuo, salivary flow rate is the most important single parameter, when considering possible associations with caries activity, and might be important as a 'threshold' limit at the individual level.[22]

In this study, it was observed that there was a statistically significant difference in resting salivary buffering capacity in all the three caries experience groups. The high and medium caries experience

Table 2: Comparison of resting salivary buffering capacity amongst subjects with different caries experience at different time intervals

CARIES EXPERIENCE		RESTING SALIVARY BUFFERING CAPACITY AT DIFFERENT TIME INTERVALS											
		BASE LINE			6 WEEKS			12 WEEKS			24 WEEKS		
		1	2	3	1	2	3	1	2	3	1	2	3
HIGH		9	13	8	10	11	9	7	13	8	8	13	9
MEDIUM		9	13	8	6	16	8	7	14	7	7	12	11
FREE		2	9	19	3	9	18	1	1	2	2	11	17
Kruskal Wallis ANOVA	χ^2	12.46			8.612			8.776			6.378		
	p value	0.002(HS)			0.013(S)			0.012(S)			0.041(S)		
Mann Whitney U test		F>M (p=0.002) F>H (p=0.002			F>M (p=0.014) F>H (p=0.009)			F>M (p=0.001) F>H (p=0.014)			F>M (p=0.04) F>H (p=0.015)		

HS – Highly significant, S – Significant, NS – Not significant
Caries Experience: H – High, M- Medium, F – Caries Free.
Buffering capacity: 1= < 4.1, 2= 4.1-5.5,3= > 5.5.

Table 3: Comparison of resting salivary Mutans streptococci counts amongst subjects with different caries experience at different time intervals

CARIES EXPERIENCE		RESTING SALIVARY MUTANS STREPTOCOCCI COUNT AT DIFFERENT TIME INTERVALS											
		BASE LINE			6 WEEKS			12 WEEKS			24 WEEKS		
		1	2	3	1	2	3	1	2	3	1	2	3
HIGH		1	7	22	0	4	26	0	3	27	0	3	27
MEDIUM		6	23	1	3	25	2	2	26	2	2	26	2
FREE		26	4	0	27	3	0	27	3	0	27	3	0
Kruskal Wallis ANOVA	χ^2	71.904			72.200			74.516			59.545		
	p value	<0.001(HS)			<0.001(HS)			<0.001(HS)			<0.001(HS)		
Mann Whitney U test		M>F (p<0.001) H>M (p<0.001) H>F (p=0.002)			M>F (p<0.001) H>M (p<0.001) H>F (p=0.002)			M>F (p<0.001) H>M (p<0.001) H>F (p=0.002)			M>F (p<0.001) H>M (p<0.001) H>F (p=0.002)		

HS – Highly significant, S – Significant, NS – Not significant
Caries Experience: H – High, M- Medium, F – Caries Free.
Mutans streptococci count (in CFU/ml): 1= $<10^5$, 2= $\geq 10^5$ - $<10^6$, 3= $\geq 10^6$.

groups had significantly higher resting and stimulated salivary buffering capacity in relation to the caries free group. The results are in accordance with numerous studies conducted by Farsi in Saudi Arabia[2], Tukia-Kumala et. al. in Finland[4], Holbrook in Iceland[17], Gopinath et. al. in Malaysia[15] and Malekipour et. al. in Iran. [23] In all these studies the dental caries prevalence was significantly higher in caries active groups than caries free groups.

The results are however in contrast with the results of studies conducted by Gabris et. al. in Hungary[24] and Preethi et. al. in Davangere. [25] The reason for this observed contrast in results could be due to the fact that other factors like microflora, diet and retention of food might have dominated the buffering capacity to initiate caries, which is a multifactorial disease, as justified by the author in the Davangere study.

Due to their positive numerical association with human caries and the linkage of this association to carbohydrate consumption, counts of Lactobacilli and Mutans streptococci may, potentially, serve not only as a caries risk predictor but also as an indicator of carbohydrate consumption, another caries-risk factor. [26]

In this study, the Mutans streptococci counts and Lactobacillus counts were thus evaluated in saliva. Mutans streptococci were cultured using Mitis salivarius bacitracin agar and Lactobacilli in Rogosa agar, which are the selective media for the growth of, Mutans streptococci and Lactobacilli respectively. Studies reveal that the results obtained by this culture plate method, as used in this study, correlate well with the dipslide methods[4], yet another method used for the same.

It was observed that there was a statistically significant difference in resting salivary Mutans streptococci count and Lactobacillus count amongst subjects with different caries risk at all time intervals. The subjects with high caries risk showed significantly high Mutans streptococci and Lactobacillus in comparison to subjects with medium risk and caries free subjects. There was also a significant difference in Mutans streptococci counts and Lactobacilli among medium and low caries group at all the time intervals. The results obtained are in accordance with a vast majority of the studies conducted to analyse this relation. [4,24,27-36]. None of the subjects in caries free group showed ≥ 10^6 CFU/ml counts of Mutans streptococci.

However few studies conducted by Farsi in Saudi Arabia[2] and Garnath et. al. in Sweden[26] show no significant relation between dental caries experience and Mutans streptococci and Lactobacilli. In the study conducted by Garnath et al., the authors attribute the reason for the results to a probably skewed distribution subjects in dmfs classes for lower bacterium classes than for higher bacterium classes. [26]

In relation to the evaluation of salivary variables at different time intervals, it was observed that over a period of 24 weeks, none of the caries risk groups studied showed statistically significant difference in salivary factors at the different time intervals. The observation was in accordance with a study conducted by Tukia-Kumala et. al. in Finland[4], among same age group subjects over a period of 9 months.

Table 4: Comparison of resting salivary Lactobacilli counts amongst subjects with different caries experience at different time intervals

CARIES EXPERIENCE		RESTING SALIVARY LACTOBACILLI COUNT AT DIFFERENT TIME INTERVALS											
		BASE LINE			6 WEEKS			12 WEEKS			24 WEEKS		
		1	2	3	1	2	3	1	2	3	1	2	3
HIGH		1	5	24	0	6	24	0	5	25	0	5	25
MEDIUM		5	15	10	4	20	6	5	19	6	4	20	6
FREE		14	13	3	13	14	3	12	14	4	12	14	4
Kruskal Wallis ANOVA	χ2	32.812			38.427			37.198			37.596		
	p value	<0.001(HS)			<0.001(HS)			<0.001(HS)			<0.001(HS)		
Mann Whitney U test		M>F (p<0.001) H>M (p=0.005) H>F (p=0.002)			M>F (p<0.001) H>M (p=0.015) H>F (p=0.002)			M>F (p<0.001) H>M (p=0.045) H>F (p=0.002)			M>F (p<0.001) H>M (p=0.043) H>F (p=0.002)		

HS – Highly significant, S – Significant, NS – Not significant
Caries Experience: H – High, M- Medium, F – Caries Free.
Lactobacilli count (in CFU/ml): 1= <10^5 , 2= ≥10^5 - <10^6, 3= ≥10^6 .

Table 5: Comparison of resting salivary flow rate amongst subjects at different time intervals

TIME INTERVAL		RESTING SALIVARY FLOW RATE								
		HIGH CARIES			MEDIUM CARIES			CARIES FREE		
		2	3	4	2	3	4	2	3	4
BASE LINE		17	13	0	1	27	2	0	4	26
6 WEEKS		16	14	0	0	28	2	0	4	26
12 WEEKS		15	15	0	0	28	2	0	1	29
24 WEEKS		17	10	0	0	27	3	0	3	27
Kruskal Wallis ANOVA	χ2	2.204			0.795			0.366		
	p value	0.531(NS)			0.851(NS)			0.947(NS)		

HS – Highly significant, S – Significant, NS – Not significant
Caries Experience: H – High, M- Medium, F – Caries Free
Flow rate: 1= <0.1 ml/min., 2= 0.1-0.25 ml/min., 3= 0.25-0.35 ml/min., 4= >0.35 ml/min.

Table 6: Comparison of resting salivary buffering capacity amongst subjects at different time intervals

TIME INTERVAL		RESTING SALIVARY FLOW RATE								
		HIGH CARIES			MEDIUM CARIES			CARIES FREE		
		1	2	3	1	2	3	1	2	3
BASE LINE		9	13	8	9	13	8	2	9	19
6 WEEKS		10	11	9	6	16	8	3	9	18
12 WEEKS		7	13	10	7	14	9	1	11	18
24 WEEKS		8	13	9	7	12	11	2	11	17
Kruskal Wallis ANOVA	χ2	0274			0.786			0619		
	p value	0.965(NS)			0.853(NS)			0.892(NS)		

HS – Highly significant, S – Significant, NS – Not significant
Caries Experience: H – High, M- Medium, F – Caries Free.
Buffering capacity: 1= < 4.1, 2= 4.1-5.5, 3= > 5.5.

Table 7: Comparison of resting salivary Mutans streptococci counts amongst subjects at different time intervals

TIME INTERVAL		RESTING SALIVARY MUTANS STREPTOCOCCI COUNTS								
		HIGH CARIES			MEDIUM CARIES			CARIES FREE		
		1	2	3	1	2	3	1	2	3
BASE LINE		1	7	22	6	23	1	26	4	0
6 WEEKS		0	4	26	3	25	2	27	3	0
12 WEEKS		0	3	27	2	26	2	27	3	0
24 WEEKS		0	3	27	2	26	2	27	3	0
Kruskal Wallis ANOVA	χ2	1.053			1.859			0.701		
	p value	0.788(NS)			0.602(NS)			0.873(NS)		

HS – Highly significant, S – Significant, NS – Not significant
Caries Experience: H – High, M- Medium, F – Caries Free.
Mutans streptococci count (in CFU/ml): 1= $<10^5$, 2= $\geq 10^5$ - $<10^6$, 3= $\geq 10^6$.

Table 8: Comparison of resting salivary Lactobacilli counts amongst subjects at different time intervals

TIME INTERVAL		RESTING SALIVARY LACTOBACILLI COUNTS								
		HIGH CARIES			MEDIUM CARIES			CARIES FREE		
		1	2	3	1	2	3	1	2	3
BASE LINE		1	5	24	5	15	10	14	13	3
6 WEEKS		0	6	24	4	20	6	13	14	3
12 WEEKS		0	5	25	5	19	6	12	14	4
24 WEEKS		0	5	25	4	20	6	12	14	4
Kruskal Wallis ANOVA	χ2	0.481			0.880			0.262		
	p value	0.923(NS)			0.830(NS)			0.967(NS)		

HS – Highly significant, S – Significant, NS – Not significant
Caries Experience: H – High, M- Medium, F – Caries Free.

CONCLUSION

There was a significant variation of the salivary factors studied namely salivary flow rate, buffering capacity, Mutans streptococci counts and Lactobacilli counts among all the three caries experience groups (High, medium and caries free) in resting saliva.

When the individual variations of salivary factors were analysed over a period of 24 weeks, although variation of salivary factors existed among all the caries experience groups at all time intervals studied, the variation was not statistically significant. The study thus indicated that the salivary variables studied are a valuable diagnostic tool to assess caries experience and predict caries risk.

REFERENCES

1. Shafer WG, Hine MK and Levy BM. A text book of oral pathology 5th Ed Philadelphia W. B. Saunders company.1993;567-658
2. Farsi N. Dental Caries in Relation to Salivary Factors in Saudi Population Groups. J Contemp Dent Pract 2008;9(3):016-23.
3. Norman O Harris, Franklin Garcia Godoy. Primary Preventive Dentistry. 6th. Edition Prentice Hall Publishers 2003.
4. Helena Tukia-Kulmala, Jorma Tenovuo. Intra and inter-individual variation in salivary flow rate, buffer effect, lactobacilli and mutans streptococci among 11- to 12- year-old school children. Acta Odontologica Scandinavica 1993;51:31-7.
5. Shahrabi M, Nikfarjam J, Alikhani A, Akhoundi N, Ashtiani M, Seraj B. A comparison of salivary calcium, phosphate, and alkaline phosphatase in children with

severe, moderate caries, and caries free in Tehran's kindergartens. J Indian Soc Pedod Prev Dent 2008;26:74-7

6. Tenovuo JO, Odont D. Human saliva: a clinical chemistry and microbiology 1989; volume 1:27-28.Florida:CRCPress,Inc.

7. Ericson D, Bratthall D. Simplified method to estimate salivary buffer capacity.

8. Mackie and Mc Cartney. Practical Medical Microbiology 14th Edn. Elsevier Publications. 2007

9. Stookey GK. The effect of saliva on dental caries. J Am Dent Assoc 2008; 139: 11S-17S.

10. Sevón L, Laine MA, Karjalainen S, Doroguinskaia A,Helenius H , Kiss E and Veromaa ML. Effect of Age on Flow-Rate, Protein and Electrolyte Composition of Stimulated Whole Saliva in Healthy, Non-Smoking Women. The Open Dentistry Journal, 2008,2,89-92

11. Das UM, Beena JP, Azher U. Oral health status of 6 and 12 year old school going children in Bangalore city: An epidemiological study. J Ind Soc Pedod Prevent Dent 2009;27(1):6-8.

12. Goel P, Sequeira P, Peter S. Prevalence of dental disease amongst 5-6 and 12-13 year old school children of Puttur Municipality, Karnataka State-India. J Ind Soc Pedod Prevent Dent 2000;11-7

13. Van Houte J. Microbiological predictors of caries risk. Adv Dent Res 7(2):87-96

14. Edgar WM. Saliva : its secretion, composition and functions. Br Dent J 1992; 172:305-10.

15. Gopinath VK, Arzreanne AR. Saliva as a Diagnostic Tool for Assessment of Dental Caries. Archives of Orofacial Sciences 2006; 1:57-9

16. Navazesh M, Christensen CM. A comparison of whole mouth resting and stimulated salivary measurement procedures. J Dent Res 1982;61:1158-62

17. Holbrook WP. Dental Caries and cariogenic factors in pre-school urban Icelandic chidren. Caries Research 1993;27:431-7.

18. Sawair AS, Ryalat S, Shayyab M, Saku T. The Unstimulated Salivary Flow Rate in a Jordanian Healthy Adult Population. J Clin Med Res 2009;1(4):219-5.

19. Guggenheimer J, Moore PA. Xerostiomia: Etiology, recognition and treatment. J Am Dent Assoc 2003;134:61-9

20. Parvinen T, Larmas M. The Relation of Stimulated Salivary Flow Rate and pH to Lactobacillus and Yeast concentrations in saliva. J. Dent Res 1981;60:1929-35.

21. Bretz WA, Djahjah C, Almeida RS, Hujoel PP, Loesche WJ. Relationship of microbial and salivary parameters with dental caries in Brazilian pre-school children. Comm Dent Oral Epi 1992;20:261-4.

22. Tenovuo J. Salivary parameters of relevance for assessing caries activity in individuals and populations. Community Dent Oral Epidemiol 1997;25:82-6.

23. Malekipour RM, Messripour M, Shirani F. Buffering capacity of saliva in patients with active dental caries. Asian J Biochem 2008; 3(5):280-3

24. Gabris K, Nagy G, Madlena M, Denes Zs, Marton S, Keszthelyi G, Banoczy J. Associations between microbiological and salivary caries activity tests and caries experience in Hungarian adolescents. Caries Research 1999;33:191-5.

25. Preethi BP, Anand P, Reshma D. Evaluation of flow rate, ph, buffering capacity, calcium, total protein and total antioxidant levels of saliva in caries free and caries active children -An in vivo study. Biomedical Research 2010;21(3):289-94.

26. Granath L, Cleaton- Jones P, Fatti LP and Grossman ES. Prevalence of Dental Caries in 4- to 5-Year-Old Children Partly Explained by Presence of Salivary Mutans Streptococci. J Clin Microbiol 1993;33(1):66-70.

27. Russel JI, MacFarlane TW, Aitchison TC, et al. Salivary levels of mutans streptococci, Lactobacillus, Candida and Veillonella species in a group of Scottish adolescents. Community Dent Oral Epidemiol 1990;18: 17-21.

28. Kohler B, Bjarnason S. Mutans streptococci, lactobacilli and caries prevalence in 11 and 12 year old Icelandic children. Community Dent Oral Epidemiol 1987;15:332-5

29. Klock B, Svanberg M, Peterson LG. Dental caries, mutans streptococci, lactobacilli and salivs secretion rate in adults. Community Dent Oral Epidemiol 1990;18:249-52.

30. Soderling E, Pienihakkinen K, Alanen ML, Hietaoja M, Alanen P. Salivary flow rate, buffer effect, sodium, and amylase in adolescents: a longitudinal study. J Dent Res 1993;101:98-102.

31. Hegde PP, Ashok Kumar BR, Ankola VA. Dental caries experience and salivary levels of Streptococcus mutans and Lactobacilli in 13 -15 year old children in Belgaum city, Karnataka. J Indian Soc Pedo Prev Dent 2005;23-6.

32. Wilson RF, Ashley FP. Identification of caries risk in schoolchildren: salivary buffering capacity and bacterial counts, sugar intake and caries experience as predictors of 2-year and 3-year caries increment. Br. Dent Jol. 1989;167(3):99-102

33. Campus G, Lumbau A, Bachisio SL. Caries experience and streptococci and lactobacilli salivary levels in 6–8-year-old Sardinians. Int Jol Ped Dent 2000;10(4):306-12

34. Nishikawara F, Katsumura S, Ando A, Tamaki Y, Nakamura Y, Sato K, Nomura Y, Hanada N. Correlation of cariogenic bacteria and dental caries in adults. J Oral Sci 2006; 48(4):245-51

35. Gábris K, Nagy G, Madléna M, Dénes Z, Márton S, Keszthelyi G, Bánóczy J. Associations between microbiological and salivary caries activity tests and caries experience in Hungarian adolescents. Caries Res. 1999 May-Jun;33(3):191-5.

36. Granath L, Cleaton-Jones P, Fatti LP, Grossman ES. Salivary lactobacilli explain dental caries better than salivary mutants streptococci in 4-5-year-old children. Scand J Dent Res 1994,102:319-23.

ORIGINAL RESEARCH ARTICLE

EXPLORING ORAL HYGIENE PRACTICES AND PERIODONTAL STATUS OF FISHERMEN POPULATION OF MAHE- A CROSS SECTIONAL STUDY

ABSTRACT

Background: Oral Health Status of humanity is largely reliant on factors like social status, cultural values, standard of living, habits etc. Poor oral hygiene paired with disturbances in social environment can incline to various oral health problems. Fishermen are people living in isolation with their traditional values, practices, beliefs and myth intact. The fisher folk community of our country belongs to lower socioeconomic class, they reside in defined geographic area along the coastline. Objectives: The objectives of the study were to assess the oral hygiene practices and periodontal status of the fisher folk communities of Mahe.

Methods: The study was conducted among a proportionate sample of 362 fishermen population in 15 wards of entire Mahe municipality. Prior permission was obtained from secretary of fishermen co-operative society. The oral health practices were measured using a pretested questionnaire. The periodontal status was recorded on the WHO oral health assessment form 1997 (modified) and the examination was carried out under natural light by using mouth mirrors and CPI probe.

Results: Among the study participants, only 37.84% had healthy periodontal status, 45.3% used tooth brush and tooth paste for cleaning their teeth, 53.3% brushed once daily, 79.2% had mouth rinsing habit after eating, 91.9% had tongue cleaning habit, 39.7% used tooth picks as oral hygiene aids, 45.2% brushed their teeth both at morning and night.

Conclusion: Periodontal disease which is highly prevalent in the community can be minimized by appropriate interventions such as oral health education and oral prophylaxis. Regarding oral hygiene practices, the use of toothbrush and toothpaste was reported by the majority, but there is a lack of knowledge among them about the proper hygiene practices.

Keywords: Fishermen, Oral hygiene, Periodontitis, Mahe

J Odontol Res 2013;1(2):34-42

Authors:
Anzil K. S. Ali[1],
Peter Simon Sequeira[2],
Jithesh Jain[3],
Mahesh H.[4],
Vivek S.[4],
Supreetha S.[4]

[1]Post Graduate Student, Department of Public Health Dentistry, Coorg Institute of Dental Sciences, K. K. Campus, Magula, Virajpet 571 218, Karnataka, India.

[2]Principal, Coorg Institute of Dental Sciences, K. K. Campus, Magula, Virajpet 571 218, Karnataka, India.

[3]Professor and Head, Department of Public Health Dentistry, Coorg Institute of Dental Sciences, K. K. Campus, Magula, Virajpet 571 218, Karnataka, India.

[4]Senior Lecturer, Department of Public Health Dentistry, Coorg Institute of Dental Sciences, K. K. Campus, Magula, Virajpet 571 218, Karnataka, India.

Address for correspondence:
Dr. Anzil K. S. Ali, Post Graduate Student, Department of Public Health Dentistry, Coorg Institute of Dental Sciences, K. K. Campus, Magula, Virajpet 571 218, Karnataka, India.
E mail: anzilksali@gmail.com.

INTRODUCTION

Oral health status is the cumulative result of the progressive and relatively restful phases of oral diseases during a life time. The variations in oral health status of mankind is largely dependent on factors like social status, cultural values, standard of living habits and geographic location.[1]

In India, various surveys conducted have revealed an increasing trend of dental caries in the past four decades. It is said that every second person above the age of 35 years has gum pockets. In India 85% of total teeth extracted after 30 years are due to periodontal diseases.[2]

Almost eighty per cent of the Indian population reside in rural areas and have no access to dental care and the majorities are illiterate.[3]

One such group, which belongs to lower socio-economic class in India, is the fisher folk community. The fisher folk community of our country belongs to lower socioeconomic class, they reside in defined geographic area along the coastline. Fishing is still a sizable industry and one of the most dangerous occupations. It is said that fisher folk use tobacco products to avoid sea sickness and to stay awake during the night, while working at sea and have the habit of consuming alcohol after a day's hard work. Tobacco use in various forms including smoking and chewing has been an integral part of the community life in Kerala for centuries.[4]

Most of the people in this community have only minimal education, low income and are unaware of the effects of risk factors like tobacco and alcohol use on oral health. The diet of fisher folk usually lacks in fruits and vegetables and meals are eaten at very erratic intervals. Their unusual working patterns involving long periods of time at sea and only short period of time on shore make fishermen difficult to contact thereby making them a challenging study population. So, very few studies have been conducted in this community.

Mahe, also known as Mayyazhi is one of the region of the Union Territory of Pondicherry, is having a coastal line of 1.37 Km. and 15 Sq.Kms. stretches on the West Coast with fishermen population of about 6000.[5]

Hence, this study is undertaken to assess the periodontal status and oral mucosal conditions of fishermen population of Mahe and to provide a baseline data for planning oral health programmes.

Materials and Methods

The present epidemiologic survey was conducted to find out the oral hygiene practices and to assess the periodontal status of fishermen population of Mahe.

Profile of study area

Mahe (Mayyazhi) is a land titled as the eye brow of Arabian sea, which is very small and situated on the estuary of the Mayyazhi river and Arabian Sea. The district satiates an intelligent tourist, Indian, as well as foreign. Mahe is a tiny point in the Geographical map of Kerala, the million earner for the distant Pondicherry Government, 630 kms away from Pondicherry.

In 2011, Mahe had population of 41,934 of which male and female were 19,269 and 22,665 respectively. In 2001 census, Mahe had a population of 36,828 of which males were 17,153 and remaining 19,675 were females.[6]

Dental needs of the population are met by one private institution, one community health centre and private practitioners. The study was conducted in selected villages of Mahe.

Study population

The study population consists of individuals of age group 15-24, 25-34, 35-44, 45-54. All households of fisher folk communities residing at defined geographic area of Mahe seafront, were included in the study.

Method of Collection of Data:

The study was conducted on September 2012. Participants were members of the rural fishing population in Mahe, Union territory of Pondicherry, India who were present and agreed to examination at their homes or places of work (on the sea side). Thirty three subjects, mostly aged people, refused to participate in the study due to the fear of being examined by a dentist. All the fishermen were contacted at their houses by a house to house survey. Each one was explained about the investigator's visit. After getting consent, each person was interviewed using a pretested proforma. After the interview they were

examined by using mouth mirror, periodontal probe and torch light. For each person separate mouth mirror and periodontal probe were used. After the day's interview the Instruments were collected separately and sterilized in a steam sterilizer.

The WHO Oral Health Assessment Form (1997) [6] was reproduced from the "Oral Health Survey-Basic Methods 4th Edition and was printed. Clinical examination was done to assess periodontal status.. Informed consent was obtained prior to examination of each subject. One member of the community who was well versed in conversing with the members of the community and also in locating the areas where the community was situated was also present during the period of the study. Ethical clearance was obtained prior to conducting the study from the Institutional review board, Coorg Institute of Dental Sciences Virajpet, Karnataka, India.

Sampling method

The sampling technique followed is stratified sampling with pro-portional allocation. Total number of fishermen in Mahe is 6000. [7] Entire Mahe region is a single municipal corporation consist of 15 wards. A proportionate sample of 362 was taken from these 15 wards, Parakal (22), Choodikotta(14), Valvil(5), Mundock(10), Manjakkal(12), Chalakkara-South)(18), Cherukallayi(18), Chalakkara-North)(38), Palloor-South-West(16), Palloor-South-East(50), Palloor-North-East(79), Palloor-North-West(25), Pandakal-South(12), Pandakal - Central(36), Pandakal-North(7)

Questionnaire

A questionnaire consisting of 9 questions were used in the survey. The first part of questionnaire was about the personal data and second part collected information regarding oral hygiene practices. The questionnaire was constructed and administered in local language (Malayalam). The content validity and face validity of the questionnaire was assessed by a panel of six experts, 4 of dental educators and 2 of the legal representatives. The reliability analysis of the final questionnaire yielded a Cronbach's alpha of 0.75. The survey data so obtained were analyzed using SPSS software (Version17) for windows. Descriptive statistics were used to summarize the results.

Table-1: Distribution of study subjects by age and sex

Age In years	GENDER				Total	
	Male		Female			
	N	%	N	%		%
15-24	66	18.2	21	5.8	87	24.3
25-34	87	24	34	9.3	121	33.4
35-44	64	17.6	26	7.1	90	24.8
45-54	49	13.5	15	4.1	64	17.6
Total	266	73.3	96	26.3	362	100

Among the 362 fishermen, 87(24.3%) belonged to the age group 15-24 years, 121(33.4%) were in the age group 25-34 years, 90(24.8%) were in the age group 35-44 years and 64(17.6%) belonged to the age group 45-54 years.

Table-2: Distribution of study subjects by level of education

Level of education	Number of subjects	%
Illiterate	78	21.5
Primary school	55	15.1
Middle school	56	15.4
High school	49	13.5
Pre University	43	11.8
Diploma	57	15.8
Degree	24	6.9

Among the 362 subjects, 78(21.5%) were illiterate, 55(15.1%) had primary school education, 56(15.4%) had middle school education, 49(13.5%) had high school education, 43(11.8%) studied upto high school, 57(15.8%) had a diploma and 24(6.9%) possessed a degree.

Table-3: Distribution of study subjects by material used and frequency of cleaning teeth

Mode of cleaning of teeth	Number of subjects (%)	Frequency of cleaning teeth	Number of subjects (%)
Tooth brush and tooth paste	164(45.3)	Once daily	193(53.3)
Tooth brush and tooth powder	69(19.6)	Twice daily	90(24.8)
Finger and Tooth Powder	77(21.2)	More than twice daily	21(5.8)
Neem sticks	43(11.8)	After every meal	41(11.3)
Other methods (charcoal)	9(2.4)	Don't clean every day	17(4.6)

Among the study participants, 164(45.3%) used tooth brush and tooth paste for cleaning their teeth, 69(19.6%) used tooth brush and tooth powder, 77(21.2%) used finger and tooth powder, 43(11.8%) used neem sticks and 9(2.4%) used charcoal as their oral cleansing aids. Among the study subjects, 193(53.3%) brushed once daily, 90(24.8%) brushed twice daily, 21(5.8%) brushed more than twice daily. 41(11.3%) of the participants brushed their teeth after every meal and 17(4.6%) of the participants didn't have the habit of cleaning their teeth daily.

Table-4 :Distribution of study subjects (using tooth brush) by frequency of changing their tooth brush

Frequency of changing toothbrush	Number of subjects (%)	(%)
Once in 3 months	0	0
Once in 6 months	73	31.3
Yearly once	89	38.1
When bristles get frayed up	60	25.7
Don't know exactly	11	4.7
Total	233	64.3

Among the study participants using tooth brush for cleaning their teeth, none of them changed their brush within 3 months, 73(31.3%) changed their brush once in six months, 89(38.1%) changed their brush yearly once. 60(25.7%) changed their brush only when its bristles get frayed up and 11(4.7%) didn't know exactly the frequency of changing their brush.

Table 5: Distribution of study subjects (using tooth paste) according to the application of paste on brush

Quantity of paste applied	Number of subjects (%)
Full length of bristles	32(19.5)
Half-length of bristles	98(59.7)
Pea sized amount	34(20.7)
Total	164(45.3)

Among the study subjects using tooth paste, majority of them about 98(59.7%) applied tooth paste in half length of bristles, 32(19.5%) applied tooth paste in full length of bristles and 34(20.7%) used a pea sized amount of tooth paste.

Table-6: Distribution of study subjects by mouth rinsing and tongue cleaning habit after eating

Mouth rinsing habit	Number of subjects (%)	Tongue cleaning habit	Number of subjects (%)
Yes	287(79.2)	Yes	333(91.9)
No	75(20.7)	No	29(8.1)

Among the fishermen, 287(79.2%) had mouth rinsing habit after eating against 75(20.7%) with no such habit. Among the fishermen, 333(91.9%) had tongue cleaning habit against 29(8.1%) with no such habit.

Table-7: Distribution of study subjects according to use of other oral hygiene aids

Other oral hygiene aids used	Number of subjects	%
Mouth wash	29	8.1
Dental floss	47	12.9
Tooth picks	144	39.7
None	142	39.2

Among the study subjects, 144(39.7%) used tooth picks, 47(12.9%) used dental floss, 29(8.1%) used mouth wash as oral hygiene aids. About 142(39.2%) of the subjects did not use any of these oral hygiene aids.

Table-8: Distribution of study subjects according to the brushing time and duration of brushing.

Brushing time	Number of subjects (%)	Duration of brushing	Number of subjects (%)
Morning	101(27.9)	Less than one minute	29(8.1)
Noon(after lunch)	11(3.3)	One minute	132(36.4)
Before going to bed	87(24.3)	Two minutes	93(25.6)
Morning and night	163(45.2)	More than two minutes	108(29.8)

Majority of the fishermen 163(45.2%) brushed their teeth both at morning and night, 101(27.9%) of the subjects brushed their teeth during morning, 87(24.3%) brushed their teeth before going to bed and 11(3.3%) brushed their teeth after lunch. Among the study subjects, 132(36.4%) brushed their teeth for a minute, 108(29.8%) brushed their teeth for more than two minutes and 93(25.6%) of the subjects brushed their teeth for two minutes. 29(8.1%) of the subjects brushed for less than a minute.

Table-9: Age wise distribution of Study Population Based on the Periodontal Status

Age Groups in Years	Healthy periodontal tissue		Bleeding		Calculus		Pocket 4-5 mm		Pocket 6 mm or more		Excluded sextant	
	N	%	N	%	N	%	N	%	N	%	N	%
15-24	56	64.3	6	6.8	25	28.7	0	0	0	0	0	0
25-34	48	39.6	18	14.8	40	33.5	15	12.3	0	0	0	0
35-44	28	31.1	20	22.2	24	26.6	10	11.1	4	4.4	4	4.4
45-54	5	7.8	15	23.4	25	39.6	7	10.9	5	7.8	7	10.9

Among the study participants aged 15-24 years, fifty six (64.3%) had healthy periodontal tissue, six (6.8%) had bleeding and twenty five (28.7%) had detectable calculus. None of the participants had shallow or deep pockets. Among study participants aged 25-34 years, forty eight (39.6%) had healthy periodontal tissue, eighteen (14.8%) had bleeding and forty had detectable calculus (33.5%). Fifteen participants (12.3%) showed the presence of shallow pockets (4-5mm). None of them had deep pockets. Among study participants of aged 35-44 years, twenty eight (31.1%) had healthy periodontal tissue, twenty (22.2%) had bleeding, twenty four showed the presence of detectable calculus (26.6%). Ten (11.1%) had shallow pockets (4-5mm), four (4.4%) had deep pockets (6mm or more) and four (4.4%) sextants were excluded. Among study participants aged 45-54 years, five (7.8%) had healthy periodontal tissue, fifteen (23.4%) had bleeding and twenty five (39.6%) had detectable calculus. Seven (10.9%) had shallow pockets (4-5mm), five (7.8%) had deep pockets (6mm or more) and seven (10.9%) sextants were excluded.

Table 10: Age wise distribution of the Study Population Based on the Loss of Attachment (LOA)

Age Groups in Years	0-3 mm		4-5 mm		6-8nn		9-11 mm		12 mm or more		Excluded sextant	
	N	%	N	%	N	%	N	%	N	%	N	%
15-24	79	90.8	68	9.1	0	0	0	0	0	0	0	0
25-34	110	90.9	10	8.2	1	0.8	0	0	0	0	0	0
35-44	73	81.1	11	12.2	1	1.1	1	1.1	0	0	45	4.4
45-54	37	57.8	16	25	3	4.6	1	1.5	2	3.1		7.8

Among the study participants of age group 15-24, seventy nine (90.8%) had 0-3mm deep pockets, eight (9.1%) had 4-5mm deep pockets and none of them had pockets of 6-8mm, 9-11mm,12mm or more deep and no sextants were excluded. Among the study participants of age group 25-34, one hundred and ten (90.9%) had 0-3mm deep pockets, ten (8.2%) had 4-5mm deep pockets, one(0.8%) had 6-8mm deep pockets and none of them had pockets of 9-11mm,12mm or more deep and no sextants were excluded. Among the study participants of age group 35-44, seventy three (81.1%) had 0-3mm deep pockets, eleven (12.2%) had 4-5mm deep pockets, one(1.1%) had 6-8mm deep pockets, one(1.1%) had 9-11mm deep pockets and none of them had pockets of 12mm or more and four(4.4%) sextants were excluded. Among the study participants of age group 45-54, thirty seven(57.8%) had 0-3mm deep pockets, sixteen(25%) had 4-5mm deep pockets, three(4.6%) had 6-8mm deep pockets, one(1.5%) had 9-11mm deep pockets, two(3.1%) had 12mm or more deep pockets and five(7.8%) sextants were excluded.

RESULTS

The population consisted of 266 males and 96 females. The population under study consisted of a majority of illiterates living in isolated settlements away from the general population. Most of the people in the elderly age groups neither remembered their exact date of birth nor were they clear about their chronological age. Since ages reported by the elderly were not found to be reliable, no further stratification in age groups were done for those above 55 years in this study. Among the study participants of age group 15-24, seventy nine (90.8%) had 0-3mm deep pockets, eight (9.1%) had 4-5mm deep pockets and none of them had pockets of 6-8mm, 9-11mm,12mm or more deep and no sextants were excluded. Among the study participants of age group 25-34, one hundred and ten (90.9%) had 0-3mm deep pockets, ten (8.2%) had 4-5mm deep pockets, one(0.8%) had 6-8mm deep pockets and none of them had pockets of 9-11mm,12mm or more deep and no sextants were excluded. Among the study participants of age group 35-44, seventy three (81.1%) had 0-3mm deep pockets, eleven (12.2%) had 4-5mm deep pockets, one(1.1%) had 6-8mm deep pockets, one(1.1%) had 9-11mm deep pockets and none of them had pockets of 12mm or more and four(4.4%) sextants were excluded. Among the study participants of age group 45-54, thirty seven(57.8%) had 0-3mm deep pockets, sixteen(25%) had 4-5mm deep pockets, three(4.6%) had 6-8mm deep pockets, one(1.5%) had 9-11mm deep pockets, two(3.1%) had 12mm or more deep pockets and five(7.8%) sextants were excluded.

DISCUSSION

Many studies have been undertaken to assess the oral health status of various communities across the world, but there is a lacunae in literature on studies among fisher folk communities. This study was done to assess the oral hygiene practices and periodontal status as per CPI, loss of attachment. As of 2001 India census, Mahe had a population of 36,823, predominantly Malayalis. Males constitute 47% of the population and females 53%. Mahé has an average literacy rate of 85%, higher than the national average of 59.5%, with male literacy at 86% and female literacy at 85%. [4] But this study among fishermen shows that most of them were illiterate and only few possess a degree or a diploma. A total of 362 subjects (266 males and 96 females) were examined according to the WHO, 1997, 'Basic oral health survey methods'. The study population was divided into four groups according to age. Totally valid comparisons of the present study with other studies is difficult due to scarcity of the studies reported in the similar population. However, an attempt has been made to compare with similar studies conducted in other population groups.

Oral hygiene practices are an important determinant of oral health and oral health is an important aspect of community health. In the present study, tooth brush was used as oral hygiene aids by 64.3% of the population. This was similar to the results of the survey conducted by Dental council of India, where nearly three- fourths reported the use of a tooth brush for cleaning teeth.[9] However, a study conducted by N. Saravanan et al to assess the oral health status and treatment needs of fishermen population in coastal region of Kerala showed fishermen about 88.7% use toothbrush as their oral hygiene aids. [10] Toothpowder was used as an oral hygiene aid by 40.3% of the subjects, which is similar to the findings of the survey conducted by Dental council of India[9]. Widespread availability of oral health care products, influence of mass media and better levels of education could all be reasons for increased use of toothbrush and toothpaste by the fisher folk community. Among the fishermen, 79.2% had mouth rinsing habit after eating. This is higher than the results of the survey conducted by Dental council of India, where half the respondents in the country, across ages and more in rural areas, always rinsed the mouth after eating. [9]

When the periodontal status of the subjects was considered, it was observed that the maximum number of subjects scoring 'healthy periodontal tissue' were found in the younger age groups and the value gradually increased as the age increases which is in accordance with the study conducted by M. Jagadeesan et al and Bhat M. [2,3]

Life style factors such as tobacco, alcohol consumption and pan chewing are found to influence periodontal health. The term “lifestyle” is taken to mean a general way of living based on the interplay between living conditions in the wide sense and individual patterns of behavior as determined by sociocultural factors and personal characteristics. People with an unhealthy lifestyle have a poor periodontal status because of their aberrant brushing habits and detrimental effects of smoking. [10] Further investigation is required to confirm the association of these factors with the poor periodontal health of the fisher folk community.

CONCLUSION

The present study had a validated measuring instrument but was limited by the illiteracy of subjects. Recommendations for future research include ensuring a larger sample size to allow for a better representation of the target population and to improve external validity of results in future study. It is recommended that young persons from the same community could be selected and trained to deliver dental health education to this community. Voluntary organizations need to render care to this rural depressed community. Periodontal disease which is highly prevalent in the community can be minimized by appropriate interventions such as oral health education and oral prophylaxis. Oral care should be available at their door steps by arranging frequent health care programmes. Oral health education should be given to the fishermen population about the oral health problems and also ill effects of pernicious habits like alcoholism, smoking, and chewing habits by the available public media such as FM Radio, and advertisements because of their isolation from the shore. The fishery departments may consider distribution of toothbrushes, fluoridated toothpaste, and mouth rinses at a subsidized rate for the fishermen population.

REFERENCES

1. Butani Y, Weintraub JA, Barker JC. Oral health-related cultural beliefs for four racial/ethnic groups: Assessment of the literature. BMC Oral Health. 2008,8:26
2. Jagadeesan M, Rotti SB, Danabalan M. Oral health status and risk factors for dental and periodontal diseases among rural women in Pondicherry. Indian Journal of Community Medicine. 2003;25(1):1-7.
3. Bhat M. Oral health status and treatment needs of a rural Indian fishing community. West Indian Med J. 2008 Sep; 57(4):414-7.
4. Thankappan K.R, Thresia C.U. Tobacco use & social status in Kerala. Indian J Med Res, 2007;126(4):300-8.
5. Official Website of District Mahe (Puducherry), mahe.gov.in/ (Accessed on 28th April 2013).
6. World Health Organization. Oral health surveys, Basic methods. 4th edition, 1997.
7. http://www.censusindia.net/ (Accessed on 28th April 2013).
8. Directorate of Fisheries & Fishermen Welfare, Government of kerala
8. Bali RK, Mathur VB, Talwar PP, Chanana HB. National oral health survey and fluoride mapping 2002-2003 India. New Delhi: Dental Council of India, 2004.
9. Saravanan N, Kunjappan S.M, Reddy C.V.K, Veeresh D.J. A study to assess the oral health status and treatment needs of fishermen population in coastal region of Kerala. KDJ. October 2012;35(4):407-14.
10. Rupasree G, Vijay K.C. Effect of lifestyle, education and socioeconomic status on Periodontal Health. Contemp Clin Dent. 2010 Jan-Mar; 1(1):23-26.

REVIEW ARTICLE

SERUM TUMOR MARKERS IN ORAL CANCER - A BRIEF REVIEW

Authors:
Jithin Jose[1],
Niveditha Baiju[2],
Pramod Mathews[3],
Skariah K.S.[4]

[1]Senior lecturer,
Dept of Oral Pathology & Micobiology, Indira Gandhi Institute of Dental Sciences,
Nellikuzhy P. O., Kothamangalam 686 691,
Kerala, India.

[2]Professor &HOD,
Dept of Oral Pathology & Micobiology,
Indira Gandhi Institute of Dental Sciences,
Nellikuzhy P. O., Kothamangalam 686 691,
Kerala, India.

[3]Professor,
Dept of Oral Pathology & Micobiology,
Indira Gandhi Institute of Dental Sciences,
Nellikuzhy P. O., Kothamangalam 686 691,
Kerala, India.

[4]Senior lecturer,
Dept of Oral Pathology & Micobiology
Indira Gandhi Institute of Dental Sciences,
Nellikuzhy P. O., Kothamangalam 686 691,
Kerala, India.

Address for correspondence:
Dr. Jithin Jose,
Senior lecturer,
Dept of Oral Pathology & Micobiology,
Indira Gandhi Institute of Dental Sciences,
Nellikuzhy P. O., Kothamangalam 686 691,
Kerala, India.
E mail: jitinjos@gmail.com.

ABSTRACT

Oral squamous cell carcinoma (OSCC) is the most common malignant tumour in the oral and maxillofacial region. It is the sixth most common malignancy and is a major cause of cancer morbidity and mortality. OSCC accounts for 95% of malignant lesions of the mouth and is a major problem worldwide. The relative prevalence of oral SCC is 3-5% of all cancer. Serum tumor markers are defined as proteins with carbohydrate or lipid domains that are found circulating in blood and/or various other body fluids. Their appearance and changing concentrations are associated with the development and growth of malignant tumors. Serum or biochemical tumor markers constitute a variety of heterogenous substances that show quantitative changes during tumor development. These serum tumor markers have been used as prognostic markers for tumor recurrence or metastasis, e.g., CEA, SCCAg, Cyfra 21-1, TPS, etc. The purpose of this article is an attempt to review various serum tumor markers role in diagnosis and prognosis of oral cancer

Key words: Oral squamous cell carcinoma, Serum tumor marker, Squamous cell carcinoma antigen, Carcinoembryonic antigen, Tissue polypeptide antigen, Tissue polypeptide specific antigen, Cyfra 21-1

J Odontol Res 2013;1(2):42-6

INTRODUCTION:

The term 'cancer' has originated from Greek word Karkinos, a crab, referring to an irregular jagged shape often assumed due to local spread of carcinoma.[1] Oral cancer is an epithelial neoplasia generally beginning as a focal clonal overgrowth of altered stem cells near the basement membrane, expanding upward and laterally, replacing the normal epithelium. The neoplastic process is a beginning with normal epithelium progressing through hyperplasia to dysplasia to carcinoma in situ and invasive carcinoma.[2] The term 'oral cancer' includes a diverse group of tumors arising from the oral cavity, usually includes cancers of the lip, tongue, pharynx and oral cavity.[3]

The first known attempt to find markers for malignancy was made 2000 years ago and is described in an Egyptian papyrus, where breast cancer was distinguished from mastitis. Incidentally first tumor marker in modern medicine was identified by Bence – jones in 1846, who detected heat precipitates in samples of acidified urine from patients suffering from "Mollities ossium". In 1965 Gold et al, isolated glycoprotein molecule from specimens of human colonic cancer and thus discovered first "tumor antigen" later identified as carcino-embryonic antigen.[4]

"A tumour marker is a substance present in or produced by a tumor or by the tumor's host in response to the tumor's presence that can be used to differentiate a tumor from normal tissue or to determine the presence of a tumor based on measurement in the blood or secretions".[5] There are different types of molecular tumor markers including DNA, mRNA, proteins, antigens, or hormones measured quantitatively and/or qualitatively by appropriate assays. Tumor marker assays comprise immunohistochemical (IHC) test, quantitative immunoassays like radioimmunoassay or enzyme linked immunosorbent assay, polymerase chain reaction (PCR), western or northern blot and more recently microarrays (genomic and proteinomic) and mass spectrometry. Tumor markers could identify a disease process, a specific tissue or patient's characteristics and help in establishing the severity and extend of the disease.[6]

An ideal tumor marker is an abnormality which is specific for particular types of malignancy.[7] The tumor markers may be useful for the four following clinical purposes:

- Screening a healthy population for the presence of cancer or for detecting a group at a higher risk for developing a cancer.
- Making a diagnosis of cancer: a diagnostic tumor marker is a marker that will aid in detection of malignant disease in an individual.
- Determining the prognosis in a patient with cancer. This would provide to the clinician a tool for early prediction of tumor recurrence, progression and development of metastases, following the initial surgical removal of the cancer but without administration of adjuvant therapy.
- Monitoring efficacy of antitumoral treatment: tumor markers may predict how the patient is going to respond to a given therapy which includes surgery, radiation, chemotherapy or more recently targeted treatments.[6]

Squamous cell carcinoma antigen (SCC)

Squamous cell carcinoma antigen, a serpin associated with squamous cell carcinomas of different organs, comprises two nearly identical, approximately 45 kDa proteins, SCC-1 and SCC-2, which possess unique proteinase inhibitory properties. SCC-1 and SCC-2 reside in the cytosol of squamous cells, and their presence in the sera of patients with advanced squamous cell carcinomas is mainly due to a passive release rather than an active secretory process into the circulation. Elevated serum SCC has been detected in patients with squamous cell carcinoma of the esophagus, lung, head and neck, anal canal and uterine cervix.[8]

Carcinoembryonic antigen (CEA)

CEA is a protein found in many types of cells but associated with tumors and the developing fetus. This antigen was first discovered in patients with adenocarcinoma of the colon in 1965. It is a complex glycoprotein of molecular weight 180 kDa that is associated with the plasma membrane of tumor cells, from which it may be released into the blood. CEA represents a heterogeneous group of molecular

species that consist of single polypeptide chains with varying carbohydrate components. The ratio of protein to carbohydrate varies from 1:1 to 1:5 in CEA molecules from different tumors. CEA is metabolized primarily by the liver with a circulating half-life that ranges from one to eight days. CEA was first identified in colon cancer; an abnormal CEA blood level is specific neither for colon cancer nor for malignancy in general. Elevated CEA levels are found in a variety of cancers other than colonic, such as head and neck breast, lung, pancreas, stomach, and ovary.[6]

Serum Cytokeratin Fragments

In circulation, CK are detected either as partially degraded single protein fragments, as small complexes, or as large polymeric protein complexes. It has been reported that epitopes for CK 8 are located at amino acid (aa) residues 340-365, for CK18 at, 270-429 and for CK19 at, 311-367.[9] The half life of the CK fragments in circulation is about 10-15 h, depending upon the size of the fragment. The process that cause the release of soluble CK fragments into the circulation have not been completely elucidated but appear to involve multiple pathways including proteolytic degradation of CK in dying cells, abnormal mitosis, spillover of monomeric CK polypeptides from proliferating cells, apoptosis, etc. These CK fragments can be detected in a number of body fluids including blood, urine, cystic fluid, ascites, pleural effusions, and CSF after their release from tumor cells. It was also reported that, in normal, apparently healthy individuals, the level of CK in the circulation is low and it rises significantly in patients with carcinomas.[11]

Serum CK fragments as tumor markers

Cytokeratin fragments in serum, offer a simple, minimally invasive, cheap, and reliable tool for more efficient management of cancer. As described earlier, TPA, TPS, and Cyfra21-1 are being mainly used as prognostic markers. The levels of these CK fragments in serum can be quantified using various commercially available specific serological assays. [9]

The clinical value of determining soluble CK protein fragments in body fluids lies in the early detection of recurrence and the fast assessment of the efficacy of response to therapy in carcinomas. In addition to this, other serum tumor markers have also been examined for their value in the management of various malignancies. To list a few in HNSCC, SCCAg and CEA, in lung cancer, CEA, SCCAg, Neuron specific enolase(NSE), progastrin releasing peptide (ProGRP), in breast cancer, CA15-3, in gastrointestinal cancer CEA, CA-242, in cervix cancer CA 125, have been examined. [10]

Tissue polypeptide antigen (TPA)

Tissue polypeptide antigen (TPA) is a heterogeneous combination of molecules of molecular weight between 20-45 kDa. It was first defined as a tumor associated antigen in 1957 by Bjorklund. [12] This is one of the oldest tumor markers in use. It has been shown that TPA is immunologically related to a mixture of non-epidermal CK, like CK 8, 18, and 19. TPA is produced during the S and G2 phases of cell cycle. It is secreted into the circulation during and immediately after mitosis, it has been shown that the concentration of the antigen is higher in the tumor tissues and in the serum of cancer patients as compared to normal tissues or normal serum, respectively. Due to its broad specificity, TPA is not being used frequently as a tumor marker in recent years. [13]

Tissue polypeptide specific antigen (TPS)

The assay for tissue polypeptide-specific antigen (TPS) detects soluble fragments of cytokeratin 18, an acid cytokeratin protein present in epithelial cells. [14] Tissue polypeptide specific antigen was identified long ago in human carcinomas and cell lines by the using of antibodies directed toward insoluble tumor material. These antibodies have been shown to stain cytoskeletal intermediate filaments in HeLa cells. It is a specific cytokeratin–based assay, which detects a defined epitope structure located on the rod domain within aminoacid (aa) residues 322-342 of human CK 18 using M3 monoclonal antibody. [10]

Cyfra 21-1

This marker is recognized by two monoclonal antibodies against fragments of CK 19 in the serum. CK 19 is a type I CK which is released into the serum as soluble fragments. CK 19 is a 40 protein sequence. The epitopes of the two antibodies were determined to be within helix 2B of the rod domain of CK 19, the epitope sequences lie within the a.a sequence 311-335 for the catcher antibody Ks 19.1 and within 346-367 for the detector BM 19.21. These sequences are unique as could be confirmed from sequence database. Both these antibodies raised by immunization of mice with MCF-7 cells. It is a cytoplasmatic protein which forms the intermediate filament cytoskeleton within epithelial cells. The cytokeratins appear to be distributed in the various epithelia, according to the cell differentiation. During the malignant transformation, the epithelial cells appear to contain the same cytokeratins as do normal cells.

In vitro cleavage of CK19 protein has been reported by to occur through spontaneous caspase 3 activity, resulting in the release of Cyfra 21-1 into the supernatants of cancer cell lines. The elevation of extracellular Cyfra 21-1 concomitantly with significant increase of intracellular Cyfra 21-1 during apoptosis; furthermore, the cell dying by caspase independent death in the presence of the Z-VAD caspase inhibitor did not release measurable Cyfra 21-1. So, the release of Cyfra 21-1 has been suggested to occur in cells during intermediate stage of apoptosis, as a consequence of caspase activation, then into the extracellular space. [15]

Cyfra 21-1, as reported before, is a soluble fragment of cytokeratin 19. The assumption is that Cyfra 21-1 is released into the bloodstream during cell death, and therefore its level correlates very well with the tumour mass, or more specifically with the necrosis in the tumour, which is a function of the tumour mass. The finding that Cyfra 21-1 levels may be an independent marker and the preferred prognostic factor in head and neck cancer may indicate that this marker reflects tumour mass more accurately than it does the stage of the disease as expressed by the TNM. This findings may also have a therapeutic implication, as the tumour mass is one of the main parameters in deciding a therapeutic regimen.[16] The detection of soluble K19 fragments in the serum released by carcinoma cells by the Cyfra 21-1 assay has found broad clinical application as a marker to monitor treatment and evaluate response to therapy and has proven particularly useful in the case of squamous cell carcinomas of the lung.[5]

CONCLUSION:

Serum tumor markers have the potential to be valuable tools for diagnosis, prognosis, and treatment monitoring of different cancers. Their clinical utility has been demonstrated in lung and breast cancer and to some extent in head and neck cancers. It is apparent that these markers may also prove useful in predicting the risk of recurrence and/or involvement of regional lymph node metastasis in human oral cancers.

REFERENCES:

1. Garcia M, Jemal A, Ward EM, Center MM, Hao Y, Siegel RL, Thun MJ. Global Cancer Facts & Figures 2007. Atlanta, GA American Cancer Society; 2007:1-20.
2. Jatin K. Nagpala, Bibhu R. Das. Oral cancer: reviewing the present understanding of its molecular mechanism and exploring the future directions for its effective management. Oral Oncology 39;(2003):213-21.
3. D.T.W. Wong, R.Todd, T.Tsuji, R.B. Donoff. Molecular biology of human oral cancer. Crit Rev Oral Biol Med, 1996;7(4):319-28.
4. S.Sharma. Tumor markers in clinical practice: General principles and guidelines. Indian Journal of Pediatric Oncology, Jan-Mar 2009; vol30:1-8.
5. Rahul R Nair, Jerin K Johnson. A Dictionary to Tumor Markers and the Methods of Estimation. A review Advanced Biotech November 2008:23-32.
6. N. Voorzanger-Rousselot, P. Garnero. Biochemical markers in oncology. Part I: Molecular basis. Part II: Clinical uses. Cancer Treatment Reviews (2007);33:230-83.
7. Muhammad sarwar, Katsumi Tomiyoshi, Tomio Inique, Kazuhiro Fukazawa, Keigo Endo. Cyfra 21-1 as a tumor marker used in measuring the serum fragment of cytokeratin subunit 19 by immunoradiometric assay. Annala of nuclear medicine1994; Vol8, No.4: 301-6.

8. Katja N. Gaarenstorm, Gemma G. Kenter, Johannes M. Bonfrer, Catherina M. Korse, Baptist Trimbos. Can initial serum cyfra 21-1, SCC antigen, and TPA Levels in Squamous Cell Cervical Predict Lymph node Metastasis or Prognosis. Gynecologic Oncology 2000;77:164-70.

9. Sharada S. Sawant, Surekha M. Zingde, Milind M. Vaidya. Cytokeratin fragments in the serum: Their utility for the management of oral cancer. Oral Oncology (2008);44:722-32.

10. Sharada S. Sawant, Devendra A. Chaukar , Shreyas S. Joshi , Prerana P. Dange, Sadhana Kannan ,Shubhada Kane , Anil K. D'Cruz , Milind M. Vaidya. Prognostic value of tissue polypeptide antigen in oral squamous cell carcinoma. Oral Oncology 47;(2011):114-20.

11. Vivian Barak, Helena Goike, Katja W. Panaretakis, and Roland Einarsson. Clinical utility of cytokeratins as tumor markers. Clinical Biochemistry 37;(2004):529-40.

12. Turkan cetin, Arzu oguz, Pelin Algan, I. Safa Yildrim. The use of tissue polypeptide specific antigen as a marker in liver diseases. Turk J Gastroenterol 2003;14(3):177-80.

13. Klaus Weber, Mary Osborn, Roland Moil, Bo Wiklund, Bjom Luning. Tissue polypeptide antigen (TPA) is related to the non-epidermal keratins 8, 18 and 19 typical of simple and non-squamous epithelia: re-evaluation of a human tumor marker. The embo Journal vol.3 no.11 pp; 1984: 2707-14.

14. W Rebhandl, B Rami, J Turnbull, FX Felberbauer, K Paya1, D Bancher-Todesca, R Gherardini, M Mittlboeck, E Horcher. Diagnostic value of tissue polypeptide-specific antigen (TPS) in neuroblastoma and Wilms' tumour. British Joumal of Cancer (1998); 78(11):1503-06.

15. Michael A. Sheard, Borek Vojtesek, Marta Simickova, and Dalibor Valik. Release of Cytokeratin-18 and -19 Fragments (TPS and CYFRA 21-1) Into the Extracellular Space during Apoptosis. Journal of Cellular Biochemistry 85;2002:- 670-7.

16. I Doweck, M Barak, N Uri, E Greenberg. The prognostic value of the tumour marker Cyfra 21-1 in carcinoma of head and neck and its role in early detection of recurrent disease. British Journal of Cancer (2000);83(12): 1696-701.

REVIEW ARTICLE

DENTAL ERGONOMICS: A REVIEW

Authors:
Amit V. Mahuli[1],
Simpy Mittal Mahuli[2]

[1]Senior Lecturer,
Department of Public Health Dentistry,
Dr. D. Y. Patil Dental College and Hospital,
Dr. D. Y. Patil Vidyapeeth,
Sant Tukatam Nagar, Pimpri,
Pune 411 018, India.

Address for correspondence:
Dr. Amit V. Mahuli,
Senior Lecturer,
Department of Public Health Dentistry,
Dr. D. Y. Patil Dental College and Hospital,
Dr. D. Y. Patil Vidyapeeth,
Sant Tukatam Nagar, Pimpri,
Pune 18, India.
E mail: amitmahuli@gmail.com.

ABSTRACT

One of the most prevalent types of work-related injuries are musculoskeletal disorders. Work-related musculoskeletal disorders (WRMDs) result in persistent pain, loss of functional capacity and work disability, but their initial diagnosis is difficult because they are mainly based on complaints of pain and other symptoms. These disorders are very common in the profession of dentistry. Dentists and dental students often assume awkward physical positions while providing treatment to (a) get a better view of the intraoral cavity; (b) provide a more comfortable position for the patient; and/or (c) operate equipment and reach for instruments and supplies. Also, the disorders are preventable by following simple procedures and taking precautions while working. The field of ergonomics specifically deals with making workplaces more comfortable to work in and thereby reducing WRMDs. This update provides an overview of the application of ergonomical guidelines in the profession of dentistry.

KEY WORDS: Work-relatedmusculoskeletal disorders, dentistry, ergonomics

J Odontol Res 2013;1(2):47-53

INTRODUCTION AND BACKGROUND

Dentistry is a profession in that its clinical performance is restricted to an area covering only a few tens of millimeters(the mouth), and that it requires repeated, precise force applications. These situations demand a fixed posture that can create occupational hazards in both dentists and dental students.[1]Dental professionals are prone to musculoskeletal disorders(MSD) and occupational health problems due to the extreme static body postures and use of repetitive hand and wrist movements.[2] The prevalence of musculoskeletal disorders amongst dental professionals in various countries like Greece and Poland are as high as 62% and 92% respectively.[3,4]

In Greek, "Ergo," means work and, "Nomos," means natural laws or systems. Ergonomics is defined as a set of multidisciplinary knowledge applied to the organization of labor activities and elements that make up a job. The goal of ergonomics is to establish a safe, healthy and comfortable working environment, thereby preventing health problems and improving productivity. The data from professionals in the public dental clinics, who answered the multidimensional analytical work questionnaire suggests that they lack postural awareness can contribute to the maintenance of painful conditions and also the low commitment to self-care can perpetuate the state of musculoskeletal discomfort/pain, justifying the application of the ergonomics concepts in the workplace and systematic guidance to professionals to adopt a healthy lifestyle.[5]

Applying ergonomics to the practice of dentistry not only could provide safety benefits but a practice might also improve performance objectives through greater productivity. One of the main goals of ergonomics in dentistry is to minimize the amount of physical and mental stress that sometimes occurs day to day in a dental practice

Search Strategy[6]

A protocol was established and studies were sourced from four electronic databases. Screening and quality assessment was conducted by two authors. The databases including Pubmed, Google Scholar, EBSCO and SCOPUS were considered from inception of data base to February 2013. In addition, we hand searched World Wide Web, bibliographies of all included studies and Library of the institution for additional information.

Inclusion criteria:

Studies published with following keywords were included in the study; dental ergonomics, Musculoskeletal Disorders, dental health professionals, lower back pain, Magnification & treatment of Musculoskeletal disorders. Above mentioned keywords with various combinations using the Boolean operators were searched to get the desired literature.[7]

DISCUSSION

Various authors have defined stages of Musculoskeletal disorders to describe the severity of the disease:

Stages, according to Oliveira[8]

I. Fatigue, discomfort, localized pain without irradiation, which gets worse with work and better with rest.

II. Persistent and more intense pain, associated with paresthesia and burning feeling. It gets worse with work and home activities and causes reduction in productivity.

III. Persistent, strong, and irradiated pain, which gets some relief at rest, associated to a decrease in muscular strength and movement control, edema, and paresthesia. There is reduction of productivity or incapacity for work.

IV. Strong and continual pain, with intense suffering and irradiation to all members. It causes incapacity for any work.

Stages, according to Browne et al.[9]

I. Pain at work, ceasing at night, without sleep disturbance.

II. Pain during work that persists at night and causes sleep disturbance.

III. Pain even at rest, with sleep disturbance.

Table 1, Explains the Symptoms, Possible Causes, and Treatment Options for Common Musculoskeletal Disorders caused due to improper ergonomics in Dentistry.[10-13]

DISORDER		SYMPTOMS	POSSIBLE CAUSES	TREATMENT OPTIONS
Hand	Carpal tunnel syndrome	Numbness, pain, tingling, clumsiness; reduced muscle/grip strength, dexterity; symptoms may be worse at night	Compressed median nerve in the wrist	Night splint; increased frequency of rest/breaks; change work patterns; use large-handled instruments; anti-inflammatory drugs, B_6, diuretics; steroid treatment; surgical intervention as a last resort
Hand	Carpal tunnel syndrome	Pain, numbness, tingling in 4th and 5th fingers, the side and back of the hand; reduced dexterity and grip	Compressed ulnar nerve in the elbow	Avoid extreme elbow flexion and extension; ergonomic intervention; physical therapy; surgical intervention as a last resort
Hand	De Quervain's disease	Pain around thumb with grasping, pinching, twisting; swelling of the thumb area; decreased and painful thumb motion	Swelling/thickening of the tendons at base of thumb	Thumb spica wrist splint; hand rest; physical therapy; NSAIDs*; steroid injection; surgical intervention
Hand & Arm	Tenosynovitis	Pain, stiffness, swelling at the wrist, shoulder, elbow, hand, or finger joints; painful gripping or grasping; difficulty straightening	Swelling/thickening of tendons and related structures	Worksite ergonomic interventions; NSAIDs; minimize aggravating movements; physical therapy; steroid injections, surgical intervention as a last resort
Arm	Epicondylitis	Pain or tenderness on either side of the elbow; pain increases during activities	Tearing of the tendons from overuse of the forearm muscles	Worksite ergonomic interventions; NSAIDs; physical therapy; acupuncture; steroid injections; surgical intervention as a last resort
Arm	Radial tunnel syndrome	Dull aching pain below the elbow and on outside upper forearm; may be worse at night; may include hand pain	Compressed radial nerve	Worksite ergonomic interventions; NSAIDs; steroid injections; surgical intervention as a last resort

Shoulder	Rotator cuff problems	Pain, stiffness in shoulder with backward and upward arm movements; weakness of the rotator cuff muscles	Swelling or tearing of rotator cuff soft tissue; shoulder joint bone spurs or abnormalities	Worksite ergonomic interventions; NSAIDs; steroid injections; surgical intervention as a last resort
Shoulder	Thoracic outlet syn-drome	Pain in the shoulder, arm and/or hand; numbness and tingling of fingers; muscle weakness andfatigue; cold arm or hand	Compressed nerves or blood supply passing to the arms	Worksite ergonomic interven-tions—avoid working with hands above chest; Avoid surgery due to high rate of complications
Hand Arm Shoulder	Tendonitis	Localized and/or diffuse pain; loss of strength and motion	Irritation and inflammation of tendons	NSAIDs; minimize aggravating movements; physical therapy, massage; steroid injections; surgical intervention as a last resort
Neck Back	Myofascial pain syndrome	Pain in neck, shoulder and arm; painful "trigger points"; restricted range of motion	Overloaded neck and shoulder muscles	Mechanical, thermal, and chemical (eg, botulinum toxin) treatments to reduce pain and restore muscle function; muscle strengthening and stretching

*NSAIDs=nonsteroidal anti-inflammatory drugs, such as aspirin or ibuprofen.

Interventions for Consideration in the Dental Practice. In addition to widely recognized general interventions, consider the following interventions as well:

Exercise caution in purchasing equipment: When purchasing new equipment, dentists should consider the ergonomic ramifications of the purchase and be aware that the term "ergonomically designed" could simply be a marketing play. There are, unfortunately, no industry standards. Consequently, dentists should develop an understanding of ergonomic risk factors and the concept behind ergonomic interventions to help them make more knowledgeable decisions about instrument and equipment purchases.

Early Treatment of MSDs: Early intervention is of the utmost importance. Early symptoms in the wrist and hand respond to conservative medical management that includes rest, icing, non-steroidal anti-inflammatory drugs and splints. Early intervention could be important in order to achieve a better result at less cost and inconvenience.

Posture and stools: The posture adopted during the practice of operative dentistry has changed over the years. Originally, dentists commonly stood to provide treatment. With the introduction of four-handed dentistry in the 1960's, sitting became the preferred position. The sitting position was also an attempt to reduce the fatigue and discomfort sometimes associated with dental practice. Unfortunately, the seated working position has not eliminated the potential for discomfort or injury in dentistry. In many cases, dental care providers adopt whatever position is necessary to access the oral cavity.[14-17]

Operator Chair Ergonomic Guidelines: [16,17]

Goal: Promote mobility and patient access;

Accommodate different body sizes

Remember- one size does not fit all!

Look for:

3. Hands-free seat height adjustment
4. Adjustable foot rests
5. Adjustable, wrap-around body support
6. Seamless upholstery
7. Hydraulic controls
8. Cylinder height
9. Adjustable backrest
10. Tilting seat pan
11. Textured seat material
12. Correct wheel type
13. Armrests (optional)

Patient Positioning

Patient chair ergonomic guidelines

Goal: Promote patient comfort; maximize patient access

Look for:

1. Stability
2. Pivoting or drop-down arm rests (for patient ingress/egress)
3. Supplemental wrist/forearm support (for operator)
4. Articulating head rests
5. Hands-free operation
6. Small, thin headrest: Allows for greater leg room
7. Narrow upper back: Allows closer positioning
8. Swivel feature: Allows chair to rotate in the operatory
9. Sling or low profile arm rests: Helps the dentist to workin 8:00-10:00 positions without hitting their knees on afixed metal arm rest.
10. Large knobs: Should be absent. They hit the edge ofoperator chair, preventing close positioning.
11. Adjustable chair height

Hand Instruments

Various features of dental instruments may have an effect on ergonomic issues. These include:

- Size and shape of the entire instrument
- Diameter of the instrument handle
- Surface configuration where the instrument contacts the fingers
- Weight of the instrument including attachments
- Balance and alignment of the instrument
- Maneuverability of the instrument in space
- How well the moving parts can be manipulated

Maintenance of the cutting edge

1. A round handle, as opposed to a hexagonal handle, with hard edges will reduce muscular stress and digital nerve compression. However, a smooth, round handled instrument requires more pinching force to keep the handle from spinning in the hand.
2. Handles with shallow, circumferential grooves or with knurling (texturing) allow better friction with the fingers so that a secure grasp requires less force.
3. Small diameter, hexagonal shaped instrument handles produce a mechanical stress that may cause digital nerve compression. Resistance from retractable or coiled hoses on dental units could result in extra mechanical stress to maintain a precision grip.
4. Unbalanced instruments, such as slow speed motors, feel heavier at one end causing the operator to compensate in their grip by increasing the mechanical stress to the fingers and hand.
5. When instruments are wet and slippery or handles have smooth round surfaces force is increased to maintain a secure grip on the instrument. Force can also be affected by posture.

Lighting and Magnification:

The goal of overhead lighting is to produce even, shadow-free, color-corrected illumination that is concentrated on the operating field. Magnification helps in maintaining proper ergonomic posture

while working on patients. Eg:- Loupes, Microscope.

Four-handed Dentistry:

Dental assistants create a more efficient environment for the operator by eliminating unnecessary motion; decreasing twisting and turning movement; decreasing long reaches and unbalanced posture

Dental practitioners teach clients to take care of their teeth and gums, but they must also recognize the importance of protecting their health. The risk of musculoskeletal injury can be significantly reduced through the maintenance of strong muscles, especially the core muscles, good flexibility, and a healthy weight. Aerobic exercise is important and will assist with weight, as well as with stress reduction. Additionally, eating properly and getting sufficient sleeplessens the risk for injury. Musculoskeletal disorders can occur even when practitioners adhere to healthy principles; however, the recovery time is significantly reduced when practitioners are healthy at the onset of injury.[18]

General Recommendations[19]

1 When sitting for prolonged periods you must sit correctly with the low back in moderate lordosis. Whenever the seat has back rest you must use a lumbar roll to support the low back.

2 When sitting for prolonged periods, regular interuption of the sitting posture is essential to prevent the onset of pain. This can be achieved by standing upright, bending backward five or six times and walking about for few minutes.

3 When working in a stooped position, regular interuption of the bent posture is essential to prevent the onset or pain, this can be achieved by upright and bending backward five or six times.

4 When lifting, you should apply the correct lifting technique. In addition, you should stand upright and bend backwards five or six times immediately before and after each heavy single lift and also at regular intervals repeated lifting.

5 After vigorous activity you should restore and accentuate the lordosis by standing upright and bending backward five or six times. When you sit down to rest, you should maintain the lordosis and use a lumber roll to avoid slouching.

6 When standing for prolonged periods, you must stand correctly. Stand tall. Do not allow your back to sag into extreme lordosis.

Specific Recommendations:[19]

1 Patient chair should be placed at mid-sternal level.

2 Sitting position can be more appropriate for dental practice provided that minimizes the time period

3 The relationship between the knee to the patient chair should be at 90°.

4 Inclination angle should be minimized.

5 Using back support during treatment.

CONCLUSION

By practicising with correct postures the working capacity and productivity of dental professionals can be enhanced and thus can make a considerable difference to earning and quality of dental practice.

REFERENCES

1. Garbin AJI, Garbin CAS, Diniz DG,YaridSD. Dental students' knowledge of ergonomic postural requirements and their application during clinical care. Eur J Dent Educ. 2011;15:31-5.
2. Kar G, Mullick A. Designing with users: A case study for design of dental workspace. Proceedings of the Human Factors and Ergonomics Society 2012 pp. 652-5.
3. Alexopoulos EC, Stathi IC, Charizani F. Prevalence of musculoskeletal disorders in dentists BMC Musculoskeletal Disorders 2004, 5:16
4. Kierklo A, Kobus A, Jaworska M, Botuliński B. Work-related musculoskeletal disorders among dentists - a questionnaire survey. Ann Agric Environ Med 2011,18,79–84
5. Bitencourt RS, Ricardo MI. Prevalence of discomfort/pain complaints and related factors in dental professionals ofthe public health service in Araucaria, Parana state, Brazil. Work 2012; 41(suppl.1):5715-7.
6. Moher D, Liberati A, Tetzlaff J, Altman DG, The PRISMAGroup (2009) Preferred Reporting Items for Systematic Reviews and Meta Analyses: The PRISMA Statement. PLoS Med 6(7): e1000097. doi:10.1371/journal.pmed.1000097.
7. NHS CRD. Undertaking systematic reviews of research on effectiveness. York:NHS Centre for Reviews and Dissemination, University of York, 1996.(Report 4.)
8. Oliveira CR. Terminais e saúde: as explicaçõesdevidas. Proteção 1989;1:30-44.
9. Browne CD, Nolan BM, Faithfull DK. Occupational repetition strain injuries: guidelines for diagnosis and management. Med J Aust 1984;140(6):329-32.
10. Piligian G, Herbert R, Hearns M, et al. Evaluation and management of chronic work-related musculoskeletal disorders of the distal upper extremity. Am J Ind Med. 2000; 37(1):75-93.
11. Van Eerd D, Beaton D, Cole D, et al. Classification systems for upper-limb musculoskeletal disorders in workers: a review of the literature. J ClinEpidemiol. 2003; 56(10):925-36.
12. Stewart WF, Ricci JA, Chee E, et al. Lost productive time and cost due to common pain conditions in the US workforce. JAMA. 2003;290(18):2443-54.
13. Franco G. Ramazzini and workers' health. Lancet. 1999;354(9181):858-61.
14. Rundcrantz BL. Pain and discomfort in the musculoskeletal system among dentists. Swed Dent J Suppl 1991;76:1-102.
15. Rundcrantz BL, Johnsson B, Moritz U. Cervical pain and discomfort among dentists. Epidemiological, clinical and therapeutic aspects. Part 1. A survey of pain and discomfort. Swed Dent J 1990;14:71-80.
16. Valachi B, Valachi K. Preventing musculoskeletal disorders in clinical dentistry: Strategies to address the mechanisms leading to musculoskeletal disorders. J Am Dent Assoc 2003;134:1604-12.
17. Harrison D, Harrison S, Croft AC, Harrison DE, Troyanovich SJ. Sitting biomechanics, part 1: Review of literature. J Manipulative PhysiolTher1992;22:594-609.
18. Franzblau A, Werner RA. What is carpal tunnel syndrome?JAm Med Assoc1999; 282(2):186-7.
19. Sachdeva J, Gupta A. Ergonomic principles in dental setting- part 2. Guident. 2012;2:81-4.

REVIEW ARTICLE

A TECHNIQUE FOR MAXILLARY DENTURE DUPLICATION

Author:
Sanju John Jolly[1]
Seema George[1]
Pius AV[2]
Cinil Mathew[3]

[1]Reader,
Department of Prosthodontics,
Indira Gandhi Institute of Dental Sciences,
Nellikuzhy P. O., Kothamangalam 686 691,
Kerala, India.

[2]Professor,
Department of Prosthodontics,
Indira Gandhi Institute of Dental Sciences,
Nellikuzhy P. O., Kothamangalam 686 691,
Kerala, India.

[3]Sr. Lecturer,
Department of Prosthodontics,
Indira Gandhi Institute of Dental Sciences,
Nellikuzhy P. O., Kothamangalam 686 691,
Kerala, India.

Address for correspondence:
Dr. Sanju John Jolly,
Manjummekudiyil house,
House number- 41\209, Chakkingal road,
Palarivattom, Kochi 682 025,
Kerala State, India.
Ph: +91484-2348754, +919895580519
E mail: drsanjujj@rediffmail.com.

ABSTRACT

The copy denture technique is one that facilitates the replication of good features of an existing denture. This allows the dentist to offer patients an alternative to being without a denture during a laboratory reline of an existing denture. This article discusses a technique of denture duplication using vinyl polysiloxane impression material.

KEYWORDS: Copy denture, Interim denture, Temporary denture, Duplicate dentures.

J Odontol Res 2013;1(2):54-6

INTRODUCTION

Maintenance of adaptation of the denture base to the mucosa that covers the residual ridges is a critical part of a complete denture service. Every denture patient should be evaluated on an annual basis to determine the rate of resorption. Patients needing a laboratory reline of their existing complete dentures are often reluctant to proceed because they are embarrassed to be without them. Duplicate dentures can be fabricated from the patient's existing denture for use during the laboratory reline. The adaptation of the patient is better as the contour of the duplicate denture does not differ from the existing denture. In a patient who is not comfortable with his new denture, the existing denture can be duplicated to make the patient more comfortable. Duplicate dentures are also indicated in patients who need replacement of immediate dentures after bone resorption, and in patients who want a 'spare' set of dentures.

Various techniques have been described to make a duplicate denture using impression material,[1-3] impression tray,[4] duplicating flask[5] and cups.[6] A technique for fabricating a maxillary duplicate denture from a patient's existing denture is outlined in this report.

Procedure

1) Select a dentulous maxillary tray that corresponds to the size of the patient's existing denture.

2) Mix polyvinyl siloxane putty material (Speedex Putty, Coltene Whaledent, Ascot Parkway, Ohio, USA), load it into the impression tray, and press against the polished surface of maxillary denture (fig-1, A). Using a Bard- Parker knife, make a land area of 3mm width. Place orientation notches on land area, one in the anterior region and two in the posterior region.

3) Remove the denture and inspect for any irregularities (fig-1, B).

4) Apply petroleum jelly on the tissue surface of the denture.

5) Pour dental stone on tissue surface of the denture (fig-1, C). Ensure that the stone covers the land area formed on the putty and the orientation notch area.

6) Separate the cast from the denture. Check the ori-

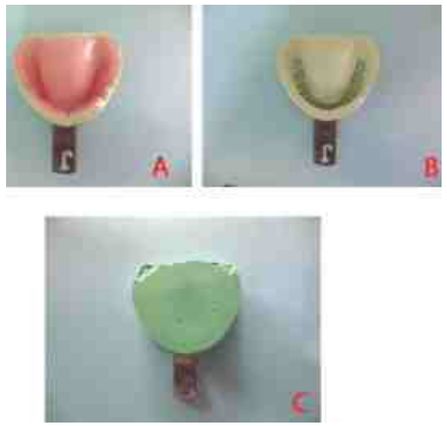

Fig. 1

Fig. 2

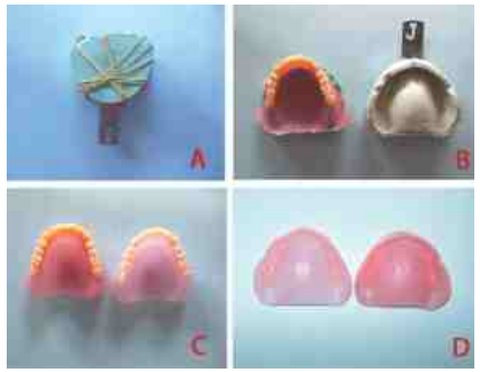

Fig. 3

entation of the cast to the notches on the putty material (fig-2, A).

7) Mix tooth coloured resin (SC-10, Wazirpur Ind. Area, Delhi, India) corresponding to the denture teeth and pour into the indentation in the putty material (fig-2, B).

8) Remove the resin after it hardens and mark the excess and trim it (fig-2, C).

9) Place the resin teeth back into the indentation (fig-2, D).

10) Apply two coats of separating media on the cast.

11) Wet the acrylic resin teeth with the monomer. Mix and pour auto polymerising resin (DPI-RR cold Cure, Dental Product Of India Ltd, Mumbai, India) into the putty and orient the cast with the help of the notches on the putty.

12) Secure the cast with the help of a rubber band (fig-3,A,B).

13) Once the curing is over, remove the denture from the cast. Trim and finish the denture in the conventional way (fig-3, C, D).

14) Evaluate the denture intra-orally. Check the fit of the denture and occlusion. It should be similar to the patients existing denture.

CONCLUSION

This technique allows the dentist to make an impression of a patient's existing denture and fabricate a duplicate denture. Patients should be informed that the duplicate denture is lower in quality in terms of strength and porosity. The esthetics, fit, and function of the duplicate denture are satisfactory for temporary use, and the minimal cost is an attractive feature to many patients. The duplicate denture should not be considered as a shortcut to new denture construction.

REFERENCES

1. Boos RH, Carpenter HO Jr: Technique for duplicating a denture. J Prosthet Dent 1974;31:329-34.
2. Singer IL. The “zipper” technique for duplicating dentures: Final impressions, replica dentures, and a complete denture splint. J Prosthet Dent 1975;33:582-90.
3. Nassif J, Jiimbelic R: Duplicating maxillary complete dentures. J Prosthet Dent 1984;52:755-59.
4. Cherian B, Nair C, Mathew M, George K, Sanjeevan V. Duplicate dentures: Impression tray technique. KDJ 2013;36(1):29-31.
5. Feltmann EF, Morrow RM, Jameson WS. Relining complete dentures with an oral cure silicone elastomer and a duplicate denture. J Prosthet Dent 1970;23:387-93.
6. Wagner AG. A temporary replacement for an existing complete denture. J Prosthet Dent 1987;58:522-25.

REVIEW ARTICLE

GROWTH ASSESSMENT PARAMETERS- AN UPDATE

Authors:
Girish V. Chour[1],
Rashmi G. Chour[2],
Pooja Latti[3]

[1]Senior Lecturer, Department of Oral and Maxillofacial Surgery, PMNM Dental College and Hospital, Bagalkot 587 101 Karnataka, India.

[2]Senior Lecturer, Department of Pedodontics, PMNM Dental College and Hospital, Bagalkot, 587 101 Karnataka, India.

[3]Senior Lecturer, Department of Public Health Dentistry, PMNM Dental College and Hospital, Bagalkot, 587 101 Karnataka, India.

Address for correspondence:
Dr. Girish V. Chour,
Senior Lecturer, Department of Oral and Maxillofacial Surgery, PMNM Dental College and Hospital, Bagalkot 587 101 Karnataka, India.
E mail: drgirish.vc@gmail.com

ABSTRACT

It is important to know the stage of maturation of a patient. Assessing maturational status, whether the pubertal growth spurt of that patient has been reached or completed, can have a considerable influence on diagnosis, treatment goals, treatment planning, and the eventual outcome of orthodontic treatment. This is especially true when clinical considerations are based strongly on the increased or decreased rates of craniofacial growth, such as the timing and use of extra oral traction, the use of functional appliances, extraction vs. non-extraction, the selection and execution of orthodontic retention, and the timing of orthognathic surgery. It is a great challenge therefore to diagnose and to plan an ideal treatment for the cases keeping in mind their growth potential, the present article reviews about the various methods of assessing the growth.

Key words: Growth assessment, maturation, parameters.

J Odontol Res 2013;1(2):57-63

INTRODUCTION

Assessing maturational status, whether the pubertal growth spurt of that patient has been reached or completed, can have a considerable influence on diagnosis, treatment goals, treatment planning, and the eventual outcome of orthodontic treatment.[1]

This is especially true when clinical considerations are based strongly on the increased or decreased rates of craniofacial growth, such as the timing and use of extra oral traction, the use of functional appliances, extraction vs. nonextraction, the selection and execution of orthodontic retention, and the timing of orthognathic surgery.[2]

The growth and development of the human face provides a fascinating interplay of form and function. The mosaic of the morphogenetic pattern, as it is influenced by epigenetic and environmental forces, requires an understanding of many factors if we are to fully appreciate the phenomenon.

Of the same chronological or calendar age have led to the concept of biologic or physiologic age. Physiologic age is the registry of the rate of progress toward maturity that can be estimated by somatic, sexual, skeletal, and dental maturity.[3]

Why to assess growth ?

The clinician is interested in assessing physical growth for the following reasons :

a) The identification of grossly abnormal pathologic growth.
b) The recognition and diagnosis of significant deviation from normal growth.
c) The planning of therapy.
d) The determination of efficacy of treatment.

William Hirschfield and Robert Moyers (1971)[3]

Several predictive methods are used in industry and science. We may group these under following headings.

1. Theoretical
2. Regression
3. Experimental
4. Time series

Theoretical Methods of Prediction:

Theoretical models of cranio facial growth have not yet been defined mathematically in terms precise enough to permit the application of the method to prediction.

Regression Methods:[3]

These methods serve to calculate a value for one variable called dependent, on the basis of its initial states and the degree of its correlation with one or more independent variables.

Johnston has recently evaluated and reviewed regression methods of approach to craniofacial prediction. Among his conclusions is that:

(1) The ultimate accuracy of cephalometric prediction may be limited to some extent by intrinsic errors with the cephalometric method itself.

(2) Contemperory methods seem inadequate to provide an efficient estimate of individual changes attributed only to growth. Burstone has reviewed some of th problems of attack and of selection of independent variables with regard to growth prediction.[4,5]

Experimental Methods:

Experimental methods are based on the clinical experience of a single investigator who attempts to quantify his observations of practice in such a way that they can be qualified for use by others. The best known example of the experimental method in craniofacial growth prediction is that of Ricketts, whose estimates of growth prediction for the individual utilize means derived from a large sample of treated orthodontic patients. The method is popular and widely used, but its theoretical base is shaky on two counts. First the assumption must be made that the individual being predicted will behave as the mean of a population of which he is not a member. Second, the morphology of the mandible and the other parts is a clue to the future growth of the face, appoint disputed by Horowitz and Hixon, Balbach and Woodside.[5]

Time Series Method:

Because of the great interest in prediction of craniofacial growth and the limitations of the methods thus far tried, it seems pertinent to ask whether there might be some other method of prediction, as yet, untried on growth problems which would provide the desired accuracy, efficiency and individuality for the clinician.

Operations research has been concerned with the development of methods which are based on individual not population behaviour.

The methods are essentially two types:

1. Time series analysis which extracts in a mathematical form the fundamental nature of the process as it relates to time.
2. Smoothing methods, either moving averages or exponential, which operate to give representative or average values to the parameters of a previously derived time series equation .For purpose of analysis a time series is considered to be composed of four parts. These are

1. Trend or long term movement
2. Oscillations about a trend
3. Cyclic or periodic events
4. Random compliments

The analysis consists of assessment of each of these parts by means of specific statistical tests. Time series method offers more promise for craniofacial growth than any of the methods thus far used.[6]

METHODS OF STUDYING PHYSICAL GROWTH[3]

There are two basic approaches for studying physical growth

1. Measuremental approaches
2. Experimental approaches

Measuremental approaches

It is based on techniques for measuring living animals, with the implication that the measurement itself does no harm and that the animal will be available for additional measurements at another time.

The science of physical anthropology began with craniometry, which is based on measurements of skulls found among human skeletal remains. From these skulls. It has been possible to piece together a great deal of knowledge about extinct populations and to get some idea of their pattern of growth. Its advantage is that rather precise measurements can be made on dry skulls. Its disadvantage is that all study is cross sectional.[7]

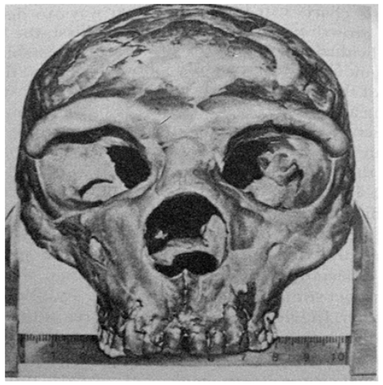

(Fig 1: Measurements taken on skull.)[7]

Craniometry[7]**:**

Craniometry is the technique of measuring the bones of the skull. It is distinct from phrenology, the study of personality and character, and physiognomy, the study of facial features. However, these fields have all claimed the ability to predict traits or intelligence.

They were once intensively practiced in anthropology, in particular in physical anthropology in the 19th and the first part of the 20th century. Theories attempting to became popular at this time, one of their prominent figures being Georges Vacher de Lapouge (1854-1936), who divided humanity into various, hierarchized, different "races", spanning from the "Aryan white race, dolichocephalic" (from the Ancient Greek kephalê, head, and dolikhos, long and thin), to the "brachycephalic" (short and broad-headed) race.

Historians study the influence and caution that science provided for racially divisive ideologies in the late 19th and early 20th century, at the height of the New Imperialism period. On the other hand, Charles Darwin used craniometry and the study of skeletons to demonstrate his first expressed in On the Origin of Species (1859).

A large skull meant a large brain and high intellectual capacity, and a small skull indicated a small brain and decreased intellectual capacity. By studying these skulls he decided at what point Caucasians stopped being Caucasians, and at what point Negroes began. Morton had many skulls from ancient Egypt, and concluded that the ancient Egyptians were not African, but was White. Later studies have since proven that this idea is false by all accounts. While few still believe it, his name has fallen into obscurity quite deeply simply because of his biased views.

It's also possible to measure skeletal dimensions on living individuals and it's called as anthropometry. It disadvantage is that soft tissue introduces variation. But on the other hand it has an advantage that it makes it possible to follow the growth of an individual directly or longitudinal study can be carried out.[2]

The third measurement technique, cephalometric radiology, combines the advantages of craniometry and anthropometry

Experimental approaches [3]

Vital staining is a technique in which dyes that stain mineralizing tissues /soft tissue are injected into an animal. The great English anatomist originated this method, John hunter in the eighteenth century. Alizarin and tetracycline are example of vital stains.

Radioactive tracers: It has been possible to use almost any radioactively labeled metabolite that becomes incorporated into the tissues as a sort of vital stain. 99mTc can be used.

Rapid advances in molecular genetics are providing new information about growth and its control. For example transforming growth factor beta-gene now is known to be important in regulating cell growth and organ development.

Another experimental method is implant radiography. In this technique inert metal pins are placed in bones anywhere in the skeleton. Professor Arne Bjork and coworkers developed this method of study. Precise evaluation of dentofacial growth in humans still is done best by implant radiography.

Relevance of growth in orthodontics:

It's difficult to comprehend conditions observed in adults without understanding of the developmental process that produced these problems. So a thorough knowledge of growth is needed.

To distinguish between normal variation from the abnormal. We need to know the normal growth pattern.

Orthodontics are 'Orthopedic Surgeon" of the craniofacial complex and are involved in the development of not just dentition but he entire dentofacial complex.

It will be easier to answer the following questions if we have thorough knowledge of growth

- Can something be done to a maxillary and mandibular growth to eliminate the dental malrelationship?
- Can we stimulate deficient jaw growth?
- Can we retard growth of one jaw in hope of gaining adjustment?
- Can we change the direction of growth?

In short, we can say that:

Treatment time, Treatment method, tooth position changes, decisions on extractions, ultimate prognosis and stability all depend on thorough knowledge of the process of growth. Some of the methods commonly used for this purpose are described here.

Frontal Sinus Development as indicator of puberty[8,9]

Sabine Ruf and Hans Pancherz (1996) evaluated the development of the frontal sinus to the longitudinal data of the subject's growth charts. Results showed that Frontal sinus growth velocity at puberty is closely related to body height growth velocity. Frontal sinus shows a well defined pubertal peak (Sp), which on an average, occurs 1.4 years after the pubertal body height peak. (Bp).If the only prediction was that whether pubertal growth maximum has passed the precision of this method was high (90 %).But if incidence of body peak was to be predicted the accuracy is only 55%.Moreover, it is only possible if 2 cephalograms approximately 1-2 yrs spaced, of the same individual are available.

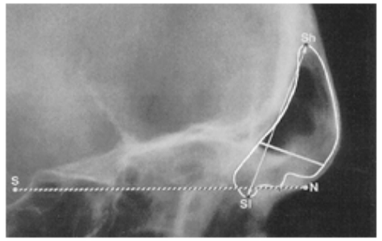

Fig:2 : Lat ceph. and graph showing growth pattern of frontal sinus. [8]

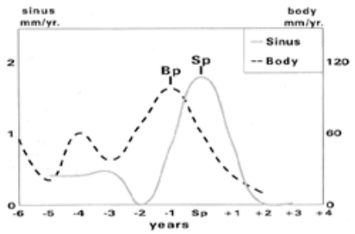

Dental Age[10]**:**

Evaluation of the dental status is of great importance for the prognostic assessment of dental development.

Chronologic and dental ages are synchronous in the normal patient. A child is labeled as an early or late developer if there is a difference of +- 2 years from the average value. If the chronologic age of the patient is younger than the dental age, one can rely on increased growth to a greater degree than when dental age is retarded in relation to the chronologic age (and possibly biologic age).

Dental age can be determined by two different methods;[10]

-stage of eruption

-stage of tooth mineralization on radiograph.

Stage of eruption:

Determination of dental age from observation of eruption has been the only method available for a long time. In most instances, it is fairly reliable. In certain cases, however, the accuracy of the method is limited. During the quiescent periods in eruption, this approach is inadequate.

Stage of tooth mineralization on radiograph:

When determining dental age radiographically according to the stage of germination, the degree of development of individual teeth is compared to a fixed scale.[10]

For age determination, one does not rely on the last stage of tooth formation but on the entire process of dental mineralization. This renders the estimation of age more accurate. The procedure can be used for the entire deciduous and mixed dentition period, and is not influenced by early loss of deciduous dentition. The calculation is made using a point evaluation system (Demirjian et al. 1973, Schopf 1970). Each tooth is given a point value according to its state of development. The sum of individual points gives the developmental value, which can be transferred into the dental age with the aid of standard tables. The smaller the sum of points, the younger is the dental age; the higher the sum the older the dental age.[2]

Bjork's Contribution to Implant Studies and Facial Growth[11]

Arne Bjork- The Man and his Work.

Arne Bjork is internationally known for his contributions to the understanding of craniofacial growth. His early publication, The Face in Profile, 1947, made him known all over the world. Bjork practiced as a clinician in Sweden for 14 years before moving to Denmark in 1951, where he chaired the Dept of Orthodontics, Royal Dental College, Copenhagen. There, Bjork combined the methods of metallic implantation and serial cephalometric roentgenography, to unravel the secrets of facial growth. His sample consisted of children attending the Department of Orthodontics, who were willing to take part in the study. Around 100 persons of each sex were included in this study, having different types of malocclusions, and ranging from 4-25 years of age. The implant method was used and annual radiographs were obtained from childhood to adulthood. The systematic superimposition of these serial radiographs with the help of implants form the basis of Bjork's studies. The results of these studies have been published in the major American and European journals since the 1950s and have become classics on the subject of facial growth.

Method and application of the use of metallic implants: [11]

Small pins of hard tantalum are hammered into bone under local analgesia with a special pencil-shaped instrument in which the implant is placed. The tantalum pins are more radiopaque than chrome cobalt alloy and retain their position in bone well. These measure 1.5mm in length and 0.5mm in diameter. A smaller pin has also been designed, measuring 1.2 x 0.37 mm. The instrument is made of stainless steel and has a hard, replaceable tip, into which the pin fits. The instrument is pressed through the periosteum to secure a firm basis before the pin is hammered in.

❖ Sites for Implant placement[12,13]

The mandible:

Before the pins are inserted, the form of the mandible and position of the dental germs are studied on the profile radiographs. Usually, 5 or 6 pins are inserted in 4 regions.

Region 1: One pin is placed on the anterior aspect of the symphysis, as low down as possible in the midline beneath the germs or root tips. This pin has proved to be highly stable, but may be exposed by resorption, if placed too high in the supramental region.

Region2: Two pins are inserted on the right side of the basal part of the mandible, under the 1st premolar and 2nd premolar (or 1st molar), beneath their germs or root apices.

Region 3: One pin is placed on the external aspect of the right ramus, on a level with occlusal surfaces of the molars. This may be gradually exposed by resorption and a new one needed.

Region 4: One or two pins are also inserted in the mandibular base on the left side, under the 2nd premolar or 1st molar. (By using small pins on the right side and larger ones on the left, they can be recognized easily.)

The Maxilla:

There are 4 regions in which implants are unlikely to be disturbed. It is usual to use six implants, preferably small ones on the right side.

Region 1: Before eruption of permanent incisors, pins are inserted, one on each side of the hard palate, behind the deciduous canines, near the median plane of the face. (Their stability depends on the extent to which the nasal floor is lowered by resorption process.)

Region 2: After eruption of the permanent central incisors, an implant is placed on each side of the median suture, below the anterior nasal spine.

These are useful for analyzing sutural growth of upper face in sagittal plane as well as transverse growth of maxilla. On each side of the head.

Region 3: At an early age, two implants can be placed in the zygomatic process of the maxilla. In order not to be disturbed by erupting teeth, these must be placed lateral to the alveolar process. Occasionally when there is a thin bone wall and maxillary sinus increases greatly during growth, one implant may be lost through the nose.)

Region 4: Implants have also been placed with good results at the border of the hard palate and the alveolar process, medially to the 1st molar.

It is standard technique to insert pins in both jaws as described.[14]

Radiographic Method [15]:

Reproducibility of head positioning in the cephalostat is very necessary in implant studies.Any discrepancies in this procedure from year to year will result in differences in projection, causing large and unacceptable errors.Bjork used a specially designed X-ray cephalostat with a built-in 5" image intensifier which would enable the position of the head to be monitored by television.

Evaluation of facial growth using serial radiographs [16]:

In order to avoid the errors associated with the tracing procedure, a printer called the Log-Etronic printer combined with an enlarger is used.By copying superimposed films by the Log-Etronic technique, a picture of the growth of the face or of a single jaw is obtained in a lateral view. These pictures are obtained by superimposing the positive films of the radiographs to be compared and making a negative Log-Etronic film of the superimposed films.

Clinical significance:[2]

1. Treatment involving modification of skeletal growth seems to demand as much as information as possible about patient's growth potential.
2. Orthodontic appliances such as the mandibular protraction appliance, Herbst appliance, Frankel, Bionator, Twin block and activator.
3. In cases where patient require orthopedic changes using head gears and protraction masks.
4. rior to rapid maxillary expansion.
5. In patients with marked discrepancy between dental and chronological age.
6. Orthodontic patients requiring orthognathic surgery if under taken during growth period.
7. When maxilla mandibular changes are indicated in the treatment of class III cases, skeletal class II cases or skeletal open bites.

CONCLUSION

As we dentists nowadays deal with more and more of mixed dentition cases, many of whom may or may not present with a skeletal malocclusion.

It is very important for us to determine the magnitude and direction of growth if we are to treat these cases with a fair amount of success.

It is a great challenge therefore to diagnose and to plan an ideal treatment for these cases keeping in mind their growth potential.

The above mentioned studies were attempts made by various people in order to ascertain the type of growth in their patients and set forth guidelines for us to follow.

However we should not forget that every individual is unique in his own aspect and therefore we should not jump to conclusions but study our patients over time and treat them to their individual requirements.

REFERENCES:

1. Moyers R. E. handbook of orthodontics 4 th edition, Chicago book medel publisher: 1988:10-17.
2. Stewart R. E, Barber T.R, Troutman K.C, Wei H.Y.Pediatric St. Louis, Taronto London: Dentistry scientific foundation and clinical practice. The C.V. Mosby CO, 1982:12-32.
3. Proffit W.R, Fields H. W. Contemporary orthodontics 3 rd edition: mosby co, 1982:27-40.
4. Khandwala H M, Mc Cutcheon I E, Flyvjerg A, Fried K E. The effects of insulin like growth factors on tumorigenesis and neoplastic growth factors. Endocrino Rev.2000;21: 215-44.
5. The assessment of growth and development in children. Arch Dis Child 1952;27(131):10-33.
6. Prevalence of overweight and obese children between 1989 and 1998: population based series of cross sectional studies. BMJ 2001: 322-6.
7. www.bonemeasurement.com
8. Frontal sinus development as an indicator for somatic maturity at puberty? American J of Othod dentofac orthop1996;110:476-82.
9. Can frontal sinus development be used for the prediction of skeletal maturity at puberty? Acta Odonntologica Scandinavica. 1996;54:229-34.
10. Demirjian,A.; Buschang, R.; Tanguay, R.; and Patterson, K.:Interrelationships among measures of somatic, skeletal, dental and sexual maturity.Am. J. Orthod.1985; 88:433-8
11. Bjork, A. and Helm, S.: Prediction of the age of maximum pubertal growth in body height, Angle Orthod. 37:134-143,1967.
12. Prediction of mandibular growth rotation. American J of Othod. 1969;55(6):585-99.
13. Facial development and tooth eruption:an implant study at the age of puberty. American J of Othod.1972; 62(4):339-83.
14. Orthodontic aspects of the use of oral implants in adolscents: a 10 year follow up study. Eur j orthod 2001;23(6):715-31.
15. Frontal sinus development as an indicator for somatic maturity at puberty? American J of Othod dentofac orthop1996;110:476-82.
16. Fishman, L.: Radiographic evaluation of skeletal maturation, a clinically oriented study based on hand-wrist films, Angle Orthod. 1982;52:88-112.

REVIEW ARTICLE

TEMPORIZATION IN ENDODONTICS - AN IMPORTANT FACTOR IN CORONAL LEAKAGE AND SUCCESSFUL OUTCOME

ABSTRACT:

In multivisit endodontic therapy temporization of teeth being treated is mandatory so as to prevent leakage of oral fluids and other contaminants into the cleaned root canal system. Thus provided temporary restorations can be either for a short duration or intended for a longer period of time based on the time taken to complete the treatment. This review article outlines the different temporization material used in endodontics and the rationale behind their usage with a brief outline on different temporization protocols and their importance.

KEY WORDS: Temporary restoration, Endodontic Temporaries, Endodontic Provisionals, Zinc oxide eugenol, Glass Ionomer, Coronal leakage.

J Odontol Res 2013;1(2):64-70

Authors:
Prasanth Dhanapal[1],
Sheena B. Prasanth [2]

[1]Professor,
Dept. of Conservative Dentistry and Endodontics,
KMCT Dental College & Hospitals,
Mampatta, Kozhikode, Kerala, India.

[2]Senior Dental Surgeon,
Quality Dental Care,
Kadavanthra, Cochin, Kerala, India

Address for correspondence:
Dr. Prasanth Dhanapal T.,
'Sahyadri',
NJRA-233, North Janatha Road,
Palarivattom, Cochin 682 025,
Kerala, India.
E mail: prasanthdhanapal@gmail.com.

INTRODUCTION:

Bacterial cause is mainly implicated in pulpal disease[1]. Pulpal inflammation or infection can cause periradicular inflammation. The main objective of endodontic treatment is to remove all possible bacteria and their by products from the root canal system and achieve the maximum disinfection of the root canal system. Many mechanical and chemical means are employed to achieve this objective.

In case of single visit endodontic therapy root canal treatment is carried out in a single visit thereby the need for temporization can be eliminated[2]. On the contrary endodontic therapy of infected root canals is suggested to be carried out in multiple visits with placement of intracanal medications within the canal for a period of time. This mandates an effective temporization of the teeth being treated[3]. Non effective temporary restoration during endodontic therapy has been even suggested as one of the contributing factors for continuation of pain after commencement of endodontic therapy[4].

Coronal Leakage and Failures

It is now a well accepted fact that leakage from the coronal aspect either during or after endodontic therapy can affect the outcome of endodontic treatment. Coronal leakage can bring about reinfection of satisfactorily endodontically treated teeth affecting its long term prognosis. Achieving fluid tight seal between visits in endodontic therapy has been advocated by many researchers since years[5]. Leakage of temporary restorations can lead to coronal leakage and in turn can negatively affect the outcome of treatment. Safavi et al[6] in an in vivo study observed greater endodontic treatment success in teeth restored with permanent restorations within 2 months of completion of root-canal therapy than teeth with temporary restorations.

Requirements for Temporaries

Temporary restoration during multivisit endodontic therapy should provide an adequate seal against ingress of bacteria, fluids and organic materials from the oral cavity to the root-canal system, and at the same time prevent seepage of intracanal medicaments placed in the canals into the oral cavity. These materials are required to allow ease of placement and removal, provide acceptable aesthetics, and protect tooth structure during treatment till a definitive restoration is placed.

Temporization of Access Cavity in Tooth

Many a materials are available to be used as temporary during conventional endodontic therapy. Most of these materials are cements that are used to seal the access between appointments. Based on the duration it can be meant for short time, moderate or interim period or a long term restorations

Zinc Oxide Eugenol Cement and its Modifications

Zinc oxide eugenol cement or many of its modifications have been used as a temporary restoration in endodontics for years and is one of the popular materials with clinicians.

Zinc Oxide Eugenol Cement: it is one of the oldest and popularly used cement for endodontic temporization. Grossman concluded that zinc oxide and eugenol (ZOE) cements provided the best seal when compared to gutta-percha and oxyphosphate cements[5]. Conventionally zinc oxide eugenol cement is mixed with a powder liquid ratio of 4:1. The mix made o f this ratio has shown to have a poor initial seal on placement. The seal have shown to improve after 1 week of placement. On the other hand a mix made of powder to liquid ratio of 2:1 gives better initial seal ability of the access cavity. But have shown to deteriorated seal with time[7]. Considering the above facts a mix with less powder to liquid ratio can be used for very short term temporization (3-5 days) of the access cavity.

Kalzinol: Kalzinol is zinc oxide eugenol based cement reinforced with 2% by weight polystyrene polymer to double the compressive strength in comparison with conventional zinc oxide eugenol cement. Kalzinol cement provided better sealing properties when compared to Cavit-W. The use of less powder is reported to improve the sealing ability without compromising much on the physical properties of the cement [7, 8]. A softer mix has also shown to exhibit greater antibacterial activity due to hydrolysis and the subsequent increase in the release of eugenol. The release of the antimicrobial agent may contribute to prevention of bacterial colonization if leakage takes place[9]. It can be useful in cases when intracanal medicaments are placed and the

time gap for the next schedule is approximately 2-3 weeks.

Coltosol: Coltosol is temporary cement indicated for short term temporization not exceeding 2 weeks. It is made up of a mixture of zinc oxide, zinc sulphate and calcium sulphate hemihydrate. The surface of Coltosol hardens upon contact with moisture within 20 to 30 minutes and achieves moderate strength to withstand mastication by 2 to 3 hours. The ease of placement makes it desirable cement and indications are the same as those of conventional zinc oxide eugenol cement endodontic temporaries.

Cavit: Cavit is a premixed temporary filling material containing zinc oxide, calcium sulphate, zinc sulphate, glycol acetate, polyvinyl acetate resins, polyvinyl chloride acetate, triethanolamine and pigments. Being a premixed material the clinician has the ease of manipulation. By virtue of water sorption Cavit exhibits a high coefficient of linear expansion, which is almost double as that of zinc oxide eugenol cement. The compressive strength of Cavit is approximately half that of zinc oxide eugenol cement. In order to compensate the poor strength qualities and to improve the marginal seal sufficient bulk of the material is to be provided as an endodontic temporary[10, 11]. A minimum thickness of 3.5 mm is needed to prevent dye leakage[11]. Cavit is indicated for endodontic temporization of access for short term and can be easily removed from the access after setting. When used for longer term surface deterioration can be a problem.

Guttapercha: Base plate gutta-percha and temporary stopping guttapercha were one of the oldest temporary materials used in endodontics. Temporary stopping guttapercha still finds its use as a temporary restorative material in many practices. It has been found to have less than ideal requirements of temporary cements in endodontics. Guttapercha based temporaries are prone to greater leakage when temperature changes happen within the oral cavity[12] and was found to be inferior to zinc oxide eugenol based cements with or without thermocycling[13].

Polycarboxylate Cement: Zinc polycarboxylate cement is not recommended for endodontic temporization by many researchers as its clinical effectiveness is not much established by studies. The sealing ability was observed to be less in comparision to zinc oxide eugenol based cements, Cavit and IRM[14]. More over removal of the temporary from the access is difficult and troublesome.

Zinc Phosphate Cement: Introduction of newer temporary materials with proven sealing ability has lead to the decline in the use of zinc phosphate cement as endodontic temporary cement. Zinc phosphate cement as access temporaries have shown to provide adequate seal against leakage in many studies[15].

Glass Ionomer Cement: Chemical adhesion to the tooth structure by glass ionomer cement contributes to the good sealing ability of the cement[16]. In one study using the fluid filtration method, glass-ionomer cement microleakage values did not differ significantly from the intact crown values after 8 weeks[17].

Glass-ionomer cements also possess antibacterial properties against many bacterial strains[18-21]. This antibacterial activity of the material is attributed to the release of fluoride, low pH and/or the presence of certain cations, such as strontium and zinc in some cement. This property is of importance in an endodontic temporary and is recommended in cases when moderately long term temporization is required. In cases when it is considered for long term temporization it is recommended to condition the exposed tooth surface with the polyacrylic acid before the cement is placed and upon insertion protect the surface of the cement using a layer of unfilled resin or varnish to minimize surface deterioration and improve the long term seal ability[22, 23]. The cost of the cement, decreased setting time and the difficulty in differentiating glass ionomer from the surrounding tooth structure during removal by the clinician are considered the drawbacks of this cement. A new material, Fuji VII Command Set has been introduced into the market mainly to be used as a temporary or an interim restorative material. Upon visible light curing this material sets in 20 to 40 seconds and chemically hardens in 4 min. this variant has a pink chroma which makes it easy to differentiate from the tooth margins. It also claims a higher fluoride release than other glass-ionomer cements.

Clinical Methodology for Temporization of Endodontic Access

Whenever an access cavity needs to be temporised the pulp chamber floor and walls should be dry. The use of a thin layer of cotton wool over canal orifices is a controversial. Usage of a cotton wool beneath the temporary cement allows for ease of removal of the temporary without running the risk of unnecessary removal of intact tooth structure or even worse, perforating the floor of the pulp chamber. Placement of cotton layer will also minimize the chance of accidental blockage of the canal by small fragments of the cement displaced into the canal.

Many drawbacks of use of a cotton layer have been reported in the literature. It may significantly reduce the thickness of the temporary cement which can lead to increase in leakage. It can also compromise the stability of the restoration by acting as a cushion allowing displacement during mastication. Cotton layer can also compromise the adaptation of the temporary cement during placement. Fibres of the cotton pellet may inadvertently adhere to the cavity walls and serve as a wick. It was also concluded that there could be an increased risk of leakage through exposed lateral canals[11, 24, 25]. The recommended procedure is either a small-sized pellet that covers the orifice but avoids the floor of the chamber, or a thin well-adapted cotton layer to cover the floor of the chamber may be used. A small sterile and well-adapted piece of polytetrafluoroethylene tape can also be used as a mechanical barrier under the temporary restoration[26]. The temporary material should be inserted in increments with good condensation into the access cavity to obtain adequate adaptation to cavity walls. The margins of the access temporary should be carefully finished and the occlusion adjusted. Removal of the temporary restoration during the procedure can be accomplished with rotary instruments or the use of ultrasonically energised tips to avoid possible complications[25] . On completion of endodontic treatment gutta-percha extending from the canal orifices should be cut back to the canal orifices level and an intermediary restoration (coronal barrier) placed to protect it.

Composite Resins As Provisional Restorations

TERM: It is a relatively new temporary restorative material introduced for endodontic purpose. It is a one component light-curable composite resin containing UDMA based polymers, radiopaque inorganic filler, prepolymerized organic filler and initiators. As with any light cured composite resin material this material also undergoes polymerization shrinkage. This shrinkage is in the range of 2.5% of its volume, which is followed by secondary water sorption associated expansion thus providing a satisfactory seal[27].

Temporization of Access Through Existing Restorations

In many cases endodontic therapy may be required in a tooth which has an existing intracoronal restoration made of amalgam or metal. If the overall condition of the restoration is good and the margins of the existing restoration donot show any evidence of leakage or failure, access can be made through these restorations. Such prepared access cavities through the intracoronal restorations can be temporized with an appropriate temporary filling material. Most of the temporary cements suggested for primary endodontic purpose can also be used to seal the access through the intracoronal restoration. On the other hand if there is any suspicion in the quality of the seal provided by the existing restoration or by the temporary material the entire existing restoration should be removed, margins examined and replaced with a new temporary material during the course of endodontic treatment [28].

Temporization of Access Through Crowns

Teeth acting as abutment for fixed bridge or with existing crowns may present for either primary endodontic treatment or re-treatment. Endodontic treatment can be completed through an access prepared and obtained in a well-fitted good quality cast restoration [29]. When the crown is of an unacceptable quality or secondary caries is present around its margins or doubts arise about the remaining tooth structure under the restoration, the crown should be removed and a provisional replacement should be provided until a definitive final restoration is placed .The access cavity through the core must be temporized between the appointments.

Temporization of Broken Down Teeth

Extensive loss of tooth structure in a badly broken

down teeth requiring endodontic therapy would hamper proper placement of the rubber dam and hence the isolation of the teeth being treated. Use of temporary cements to rebuilt the lost structure, use of copper bands and orthodontic bands as an interim measure, placement of temporary crowns have been advocated. Many of these methods have shown not to provide an adequate seal of the root canal system during the course of treatment[30]. More over many of the methods are time consuming, and gaining an access through the cements can run the risk of introducing and blocking a canal with cement particles. It has also been reported that it is difficult, if not impossible, to obtain acceptable restoration contours, marginal adaptation and occlusion[31-33] . Interim restorations to restore the lost structure employing pin-retained amalgam or composite resin to aid isolation have been suggested[32, 34] . This interim measures may Influence future restorative options after endodontic therapy and also carries the risks associated with the procedures such as pin placement and their possible removal.

Glass ionomer cement can be satisfactorily used for provisional built up[35-37] . The advantages of using GIC for provisional built up of the tooth structure includes obtaining adequate seal with the tooth structure and achieving sufficient strength and retention to withstand the forces of the application of the rubber-dam clamp. Glass ionomer is also radiopaque and can be easily placed with the possibility to commence start of endodontic treatment at the same appointment[35-37] . Once the cement sets, endodontic access can be created through the cement, followed by instrumentation and obturation in the usual manner. Less desired esthetic result may limit the use of glass ionomer as a provisional built up in the anterior segment. Use of command-set resin-modified glass-ionomer cement and relieving the tooth being treated 'out of occlusion' would be better in the management for badly broken down posterior teeth.

Composite resins is the most popular material for provisional built up of badly broken down teeth prior to and during endodontic therapy. This is attributed to the superior aesthetic results and micromechanical bonding to the prepared tooth structure[31] . Care should be taken and caution exercised if the contamination of the bonding surface can be an issue and isolation of the field cannot be assured during placement and curing of the resin composite built up[38].

Long Term Temporization

Some clinical conditions such as treatment of an open apex with apexification procedure, attempt for revascularization or treatment of root resorption may require long-term temporization. A permanent-type restoration can be used in these instances. Glass-ionomer cement can be considered for this cases as its seal ability for longer periods is established clinically[17, 23, 39]. Another alternative in such cases is use of resin composites. If composites are to be used as a material it will be preferable to seal the canal orifices with some other temporary material before placement of composite. This allows relative ease of access during the course of treatment and to prevent accidental loss of composite material into the root canal.

Temporary Restoration and its Interaction with Permanent Restorations:

Temporary or provisional material used in endodontics should not affect the polymerization or adhesion of the future permanent restorative material. Eugenol residue has shown to have a deleterious effect on the physical properties of composite resin restorations such as microhardness surface roughness and colour stability. It is recommended to use bonding systems that rely on the total-etch technique. The use of 30 to 35 % phosphoric acid for 15 seconds for etching prior to bonding will result in demineralization of dentine to a depth of approximately 10 mm and this has found to remove any residual cement. In spite of this it is preferable to avoid the use of ZOE temporary restorations in cavities to be restored permanently with composites.

CONCLUSION:

The predictability and long term prognosis of an endodontically treated teeth depends on achieving almost complete disinfection of the root canal system and achieving a three dimensional obturation of the root canal. Coronal seal is of great importance than earlier thought in maintaining the asepsis obtained and preventing percolation. A proper coronal seal can only be obtained and maintained if a good temporary restoration is employed during and immediately after endodontic therapy till a definitive restoration is in place. Every importance should be given to temporization during endodontic therapy to achieve long term success.

REFERENCES:

1. Kakehashi S, Stanley HR, Fitzgerald RJ: The effects of surgical exposures of dental pulps in germ-free and conventional laboratory rats: OOO: 1965:20:340-9.
2. Orstavik D: Intracanal medication. Pitt Ford TR, Editor. Harty's Endodontics in Clinical Practice, 4th Edn : 1997: Oxford, UK: Wright, Page: 113
3. Sjogren U, Figdor D, Persson S, Sundqvist G: Influence of infection at the time of root filling on the outcome of endodontic treatment of teeth with apical periodontitis: Int Endod Jour: 1997:30:297-306.
4. Abbott PV: Factors associated with continuing pain in endodontics: Aus Dent Jour: 1994:39:157-61.
5. Grossman LI: A study of temporary fillings as hermetic sealing agents: Jour Dent Res: 1939:18:67-71.
6) Safavi KE, Dowden WE, Langeland K: Influence of delayed coronal permanent restoration on endodontic prognosis: Endod Dent Trauma: 1987:3:187-91.
7. Pashley EL, Tao L: The sealing properties of temporary filling materials: Jour Pros Dent: 1988:60:292-96.
8. Anderson RW, Powell BJ, Pashley DH: Microleakage of IRM used to restore endodontic access preparations: Endod Dent Trauma: 1990:6:137-41.
9. Chandler NP, Heling I: Efficacy of three cavity liners in eliminating bacteria from infected dentinal tubules: Quint Inter: 1995:26:655-9.
10. Widerman FH, Eames WB, Serene TP: The physical and biologic properties of Cavit: Jour Am Dent Assoc: 1971:82:378-82.
11. Webber RT, delRio CE, Brady JM, : Sealing quality of a temporary filling material : OOO : 1978:46:123-30
12. Parris L, Kapsimalis P, Cobe H, Evans R: The effect of temperature change on the sealing properties of temporary filling materials. Part II: OOO: 1964:17:771-8.
13. Kakar RC, Subramanian V: Sealing qualities of various restorative materials: Jour Prost Dent: 1963:13:156-65.
14. Marosky JE, Patterson SS, Swartz M: Marginal leakage of temporary sealing materials used between endodontic appointments and assessed by calcium 45 - an in vitro study: Jour Endod: 1977:3:110-13.
15. Krakow AA, destoppelaar JD, GrUn P: In vivo study of temporary filling materials used in endodontics in anterior teeth: OOO: 1977:43:615-20.
16. Watson TF: Bonding glass-ionomer cements to tooth structure. In: Davidson CL, Mjor IA, editors: Advances in Glass-Ionomer cements: 1999: Chicago, USA: Quintessence Books, pages 121-35.
17. Bobotis HG, Anderson RW, Pashley DH, Pantera EA: A microleakage study of temporary restorative materials used in endodontics: Journ Endod: 1989:15:569-72.
18. Tobias RS, Browne RM, Wilson CA : Antibacterial activity of dental restorative material: Intern Endod Journ : 1985:18:161-71
19. Chong BS, Owadally ID, Pitt FordTR, Wilson RF: Antibacterial activity of potential retrograde root filling materials: Endod Dent Traum: 1994:10:66-70.
20. Heling I, Chandler NP : The antimicrobial effect within dentinal tubules of four root canal sealers : Journ Endod: 1996:22:257-9
21. Herrera M, Castillo A, Baca P, Carrion P: Antibacterial activity of glass-ionomer restorative cements exposed to cavity-producing microorganisms: Oper Dent: 1999:24:286-91.

22. Lim KC: The microleakage of a glass ionomer cement using two methods of moisture protection: Quint Intern: 1987:18:835-9.

23. Lim KC: Microleakage of intermediate restorative materials: Journ Endod: 1990:16:116-8.

24. Orahood JP, Cochran MA, Swartz M, Newton CW: In vitro study of marginal leakage between temporary sealing materials and recently placed restorative materials: Journ Endod: 1986:12:523-7.

25. Bishop K, Briggs P: Endodontic failure - a problem from top to bottom: BDJ:1995:179:35-6.

26. Stean H: PTFE tape: a versatile material in restorative dentistry: Dent Update: 1993:20:146-8.

27. Deveaux E, Hildelbert P, Neut C, Boniface B, Romond C: Bacterial microleakage of Cavit, IRM, and TERM: OOOE: 1992:74:634-43.

28. Melton D, Cobb S, Krell KV: A comparison of two temporary restorations: light-cured resin versus a self-polymerizing temporary restoration: OOOE: 1990:70:221-5.

29. Beach CW, Calhoun JC, Bramwell D, Hutter JW,Miller GA : Clinical evaluation of bacterial leakage of endodontic temporary filling materials : Journ Endod : 1996:22:459-62.

30. Walton RE: Access preparation and length determination. In: Walton RE, Torabinejad M, editors: Principles and Practice of Endodontics, 3rd edn. Philadelphia, USA: 2002: W.B. Saunders Co: page: 189.

31. Abdullah Samani SI, Harris WT: Provisional restorations for anterior teeth requiring endodontic therapy: Journ Endod: 1979:11: 340-3.

32. Kahn H: Coronal build-up of the degraded tooth before endodontic therapy: Journ Endod: 1982:8:83-4.

33. Brady WF: Composite resin interim restorations for broken-down non vital posterior teeth: JADA: 1983:106:462-6.

34. Messing JJ: Restoration of the crown-less tooth as a prelude to endodontic treatment: BDJ: 1976:140:178-80.

35. Bass EV, Kafalias MC: Provisional coronal build-up of posterior teeth for endodontic treatment. Case report: Aust Dent Journ: 1987:32:417-20.

36. Morgan LA, Marshall JG: Solving endodontic isolation problems with interim buildups of reinforced glass ionomer cement: Journ Endod: 1990:16:450-3.

37. Rice TR, Jackson RC: Tooth build-up prior to endodontic treatment: Quint Intern: 1992:23:341-4.

38. Derkson GD, Pashley DH, Derkson ME: Microleakage measurement of selected restorative materials: a new in vitro method: Journ Prost Dent: 1986:56:435-40.

39. Barthel CR, Strobach A, Briedigkeit H, Gobel UB, Roulet JF : Leakage in roots coronally sealed with different temporary fillings : Journ Endod: 1999:25:731-4.

CASE REPORT

DRUG INDUCED ORAL ERYTHEMA MULTIFORME: A CASE REPORT

Authors:
Rathy Ravindran[1],
Sunil S.[2],
Nivia M.[3]

[1]Professor & HOD, Dept of Oral & Maxillofacial Pathology, Azeezia College of Dental Science & Research, Meeyannoor, Kerala, India.

[2]Professor, Dept of Oral & Maxillofacial Pathology, Azeezia College of Dental Science & Research, Meeyannoor, Kerala, India.

[3]Post Graduate student, Dept of Oral & Maxillofacial Pathology, Azeezia College of Dental Science & Research, Meeyannoor, Kerala, India.

Address for correspondence:
Dr. Rathy Ravindran, Professor & HOD, Dept of Oral & Maxillofacial Pathology, Azeezia College of Dental Science & Research, Meeyannoor, Kerala, India.
E mail:
aswathysundaran1@yahoo.co.in.

ABSTRACT

Oral erythema multiforme presents with oral and lip ulcerations typical of erythema multiforme but without skin target lesion. The primary attack is confined to oral mucosa but subsequent attacks can produce more severe forms of erythema multiforme involving skin. It is important to distinguish it from other oral ulcerative disorders for early diagnosis and treatment. Here we report a case of oral erythema multiforme induced by drug with literature review.

Key words: Oral erythema multiforme, drug reactions, lips.

J Odontol Res 2013;1(2):71-4

INTRODUCTION

Oral Erythema Multiforme (EM) is considered as a third category of EM other than EM minor and major. Oral erythema multiforme characterized by oral mucosal ulcerations & lip lesions typical of EM without any skin lesions. Kenneth described oral lesions of EM without any skin involvement in 1968[1]. EM minor shows ulcerations involving single mucosal site with typical skin target lesions. EM major shows ulcerations involving more than one mucous membrane with skin target lesions. A wide range of antigens including herpes and drugs has been suggested as triggering the disease. Ferdinant Von Hebra first described EM in 1866[2]. Thomas coined the term erythema multiforme minor and major in 1950[3]. Here we report a case of drug induced oral erythema multiforme highlighting its importance of early diagnosis and treatment, as oral lesions precedes skin lesion of erythema multiforme.

Case Report

A 60 year old male reported to the out patient department with a chief complaint of redness and ulceration of both lips since 1 week. Patient gave history of extraction of his left upper back tooth and was prescibed Mefenamic acid [Meftal forte]. He felt burning sensation on intake of food and noticed ulcers on left buccal mucosa and the lips 3 days after taking medication.

On intraoral examination patient had multiple ulcerations of the labial mucosa and irregular ulcerations and blood encrustations of both the lips. Skin lesions were absent. Multiple ulcerations of labial mucosa and blood encrustations seen on the vermilion zone of the lip (figure 1). Provisional diagnosis of drug induced oral erythema multiforme was made. Patient was asked to stop all the medicines and given Prednisolone 5mg twice daily for 10day, Levocetrizine once daily for 10 day and Pantoprazole 40mg once daily for 10 days. Patient was asked to come for review after 10 days. On review patient showed symptomatic progress (figure 2). Prednisolone dose tapered and stopped.

DISCUSSION

Erythema multiforme(EM) is a rare, acute inflammatory disorder that affects skin, or mucous membrane or both. It present with a wide spectrum of severity. Erythema multiforme minor represents a localised eruption of the skin with mild or no mucosal involvement. Erythema multiforme major and Steven Johnson are more severe mucosal and skin diseases and are potentiallly life threatening disorders.EM occurs chiefly in young adults and peak age of presentation is 20-40 years. Peak incidence seen in second to fourth decades of life and males are more commonly affected than females[4]. The incidence of oral lesions in EM varies considerably from 25-70%. It is usually triggered by herpes simplex infections, but rarely by drug intake. The antigens are primarily microbial agents (Herpes simplex virus, mycoplasma, pneumonia and histoplasmosis), gastrointestinal conditions like Crohn's disease and ulcerative colitis, other conditions like radiotherapy and recent vaccination or drugs[5]. The most common drugs that trigger EM lesions are long acting sulfa drugs especially sulphonamides, co-trimoxazole, phenytoin, carbamazepine and nonsteroidal antiinflammatory drugs such as diclofenac, ibuprofen, and salicylates. About 5% of EM are attributed to drug intake. The positive drug history associated with onset of oral ulcerations ruled out other oral ulcerative and autoimmune vesiculobullous disease in our case. Literature review of drug induced erythema multiforme is given in Table 1.

In drug-induced erythema multiforme, the reactive metabolites of the initiating drug induce the disease[6]. Drug-induced erythema multiforme usually develops 1 to 3 weeks after exposure but may occur within hours or days which is the time it takes for an immune response to appear. Second reccurence occurs significantly shorter than that of the first episode and is indicative of a secondary immune response. Immunocytochemicial staining and in situ hybridisation has shown that the lesions are characterised by tumour necrosis factor alpha (TNF- α) present in keratinocytes. Much of the tissue damage in drug-induced lesions appears to be due to apoptosis and due to the paucity of the inflammatory reaction. Locally produced TNF-α has been shown to mediate keratinocyte apoptosis and it is possible that this mechanism plays an important role in drug induced erythema multiforme[6]. EM results from a T-cell-mediated immune reaction to the precipitating agent. It leads to cytotoxic immunological attack on keratinocytes that express non-self antigens, resulting in sub-epithelial and intra-epithelial vesiculation. Drugs or other antigens like herpes virus form circulating immune complexes that filter into the basement membrane in skin and mucosa. These components bind complement and initiates a vasculitis with thrombosis and ischemic necrosis of the overlying epithelium. This leads to wide spread blistering and erosions[5].

Intraoral lesions seen typically on the non-keratinised mucosa and most pronounced in the anterior parts of the mouth. The oral mucosal ulcerations are usually irregular and large with necrotic tissue tags. Lip ulcerations are blood encrusted. The clinical presentation of the oral lesions is typically with swollen lips, labial erosions and blood stained serosanguinous exudate.

Table 1- Cases reported with drug induced erythema multiforme[1,7,8]

AUTHOR	YEAR	DRUG
Taylor S. W et al	1989	Methotrexate
Dubey N. K et al	1995	Paracetamol
Rzany B et al	1996	Allopurinol - 18 cases Aminopencillin – 7 cases Carbamezepine – 13 cases Co – trimoxazole – 22 cases Dexamethasone – 8 cases Paracetamol – 11 cases Phenytoin – 11 cases
Amichai. B et al	1998	Methotrexate
Chen W.C et al	2002	Pyrazolone
Worhl .S et al	2005	Phenytoin
Dilhuydy M . S etal	2007	Sorafenib
Joseph T. I et al	2012	Diclofenac

Oral lesions progress through diffuse widespread macules to blisters and ulceration. Oral involvement is seen in about 70% of the cases with erythema multiforme[6]. Literature review showing oral lesion in erythema multiforme given in table 2.

Table 2 - Oral lesions in erythema multiforme [2,6,7]

AUTHOR	YEAR	NUMBER OF CASES	ORAL LESIONS
Huff and Weston	1989	22 cases	22.7%
Schofield et al	1993	65 cases	69%
Farthing et al	1995	82 cases	70%
Lamireau T et al	2000	42 cases	78.5%
Wetter and Davis	2010	48 cases	62.5%

When only oral mucosa is involved the differential diagnosis to be considered include herpes, autoimmune vesiculobullous lesions such as pemphius vulgaris or bullous pemphigoid and other patterns of drug reactions. Herpetic lesions more common on keratinized mucosa. In our case patient positive drug history, clinical appearance and distribution of lesion ruled out possibility of autoimmune vesiculobullous disease. Other clinical patterns of adverse reaction to drug like lichenoid drug reaction, pemphigoid like drug reactions can be differentiated based on clinical pattern. Anaphylactic stomatitis which often shows urticarial skin reactions signs symptoms of anaphylaxis. In fixed drug eruption, lesion is confined to localized area of oral mucosa.

Histopathologically subepithelial or intraepithelial vesiculation may be seen with necrotic basal keratinocytes. Satellite cell necrosis ie, individual eosinophilic necrotic keratinocyte surrounded by lymphocytes may be seen. Sometimes oedema results in pooling of oesinophilic coagulum within the epithelium described as keratin mucopolysaccharide dystrophy[5]. There is intense lymphocytic infiltration and vacuolar degeneration of basement membrane zone. A mixed inflammatory infiltrate is present in connective tissue consisting of lymphocytes, neutrophils and often eosinophils arranged in a perivascular orientation. Immunofluorescence reveals that deep perivasculitis is positive for antibodies of Ig M and C3[3,4,9]. Histopathological examination of the ulcerative lesion in erythema multiforme is non specific and non diagnostic[1]. Hence biopsy was not undertaken in the present case. Biopsies are advised only in early vesicular lesions of erythema multiforme.In the present case diagnosis was made based on clinical appearance and positive drug history.

Fukiwake et al in 2007 demonstrated anti - keratinocyte cell surface antibodies in the serum of a paient with oral erythema multiforme by indirect immunofluorescence. It revealed that the autoantibodies are bound to the plasma membrane of epidermal keratinocytes. Indirect immunofluorescence shows anti-desmoplakin monoclonal antibody which react with keratinocyte cell surface [DP I& II] of esophageal mucosa. On immunoblotting patient's serum showed autoantibodies reactive were DP I and II which exist in the cytoplasmic attachment plaque of desmosomes [10].

Fig1: Irregular ulcerations with blood encrustations

Fig 2: 10 days post treatment,
the oral and lip ulcerations shows healing

Managed by identification of triggering agent. If it is found to be HSV infection patients have to be put on antiviral medications. If the triggering agent is an adverse drug reaction, the drug is immediately stopped. Usually lesions of oral EM can be treated palliatively with analgesics for oral pain, viscous lidocaine rinses, soothening mouth rinses, bland soft diet, avoidance of acidic and spicy food, oral anti-histamines, systemic and topical antibiotics to prevent secondary infection. Oral antacids may be helpful for discrete oral ulcers. Lesions of EM usually respond to topical steroids, for more severe cases systemic corticosteroids are recommended[4].

CONCLUSION

Oral EM is a rare and less described variant of EM. Even though primary attacks of oral EM are confined to the oral mucosa the subsequent attacks can produce more severe forms of EM (EM minor and major) involving the skin. Hence, it is important to distinguish oral EM for their early diagnosis, proper management.

REFERENCES

1. Joseph T I, Varghese G, George D, Sathyan P. Drug induced oral erythema multiforme: A rare and less recognized variant of erythema multiforme. J Oral Maxillofac Pathol 2012;16: 145-8.
2. Lamireau.T, Chawki.D, Maleville.J, Taieb.A. Diagnosis, classification, and management of erythema multiforme and Stevens-Johnson syndrome. Arch Dis Child 2000;83:347-52.
3. Fabbri .P, Panconesi.E. Erythema multiforme and drug intake. Clinics in Dermatology, 1993;11:479-489.
4. Rajendran.R. Disease of skin. R.Rajendran, Sivapadasundaram.B,editor. Shafer's textbook of Oral Pathology, 6th edition. New Delhi: Elsevier; 2010.p.806-8.
5. Sapp J.P, Eversole L.R, Wysocki G.P. Mucosal and skin conditions. Contemporary oral and maxillofacial pathology, 2nd edition. Mosby; 2004.p.270-4.
6. Farthing P, Bagan J-V, ScullyC.Mucosal disease series Number IV Erythema multiforme. Oral diseases 2005;11:261-7.
7. WetterD.A, DavisM.D.P. Recurrent erythema multiforme: Clinical characteristics, etiologic associations, and treatment in a series of 48 patients at Mayo Clinic, 2000 to 2007. J Am Acad Dermatol 2010;62:45-3.
8. Dilhuydya M.S, Jouary.T, Gomezd.A, Wallerande.H, Pasticiere.G, Ravaud.A. Case Report 2. Severe erythema multiforme induced by two consecutive anti-angiogenic drugs. EJC supplements 5, no.7.2007; 30-1.
9. Rzany.B, Hering.O, Mockenhaupt.M, Schroder.W, Goerttler.E, Ringf.J, Schopf.E. Histopathological and epidemiological characteristics of patients with erythema exudativum multiforme major, Stevens-Johnson syndrome and toxic epidermal necrolysis. British Journal of Dermatology 1996;135:6-11.
10. Fukiwake.N, Moroi.Y, Ureabe.K, Ishii.N, Hashimoto.T, Furue.M. Detection of autoantibodies to desmoplakin in a patient with oral erythema multiforme, Eur J Dermatol 2007;17(3):238-41.

CASE REPORT

TWO UNUSUAL CASES OF PALATOGINGIVAL GROOVE

Authors:
Srilakshmi Yerapotu[1],
Vidhya Sampath[2],
Ankur Sehgal[3], Mohan B.[4],
Lakshmi Narayanan[5]

[1]Reader, Department of Conservative Dentistry and Endodontics, Vasanthadada Patil Dental College and Hospital, Sangli 444 602, Maharashtra, India.

[2]Reader, Department of Conservative Dentistry and Endodontics, SRM Dental College, Bharathi Salai, Ramapuram, Chennai 600 089, Tamil Nadu, India.

[3]Reader, Department of Conservative Dentistry and Endodontics, Surendera Dental College and Research Institute, Sri Ganga Nagar 335 001, Rajasthan, India.

[4]Professor, Department of Conservative Dentistry and Endodontics, SRM Kattankulathur Dental College, SRM University, Kattankulathur 603 203, Tamil Nadu, India.

[5]Professor and Head, Department of Conservative Dentistry and Endodontics, SRM Kattankulathur Dental College, SRM University, Kattankulathur 603 203, Tamil Nadu, India.

Address for correspondence:
Dr. Srilakshmi Yerapotu,
Reader, Department of Conservative Dentistry and Endodontics, Vasanthadada Patil Dental College and Hospital, Sangli 444 602, Maharashtra, India.
E mail: ymr357@yahoo.com.

ABSTRACT

Endo-perio lesions are common in everyday practice. Palatogingival groove is one such developmental anamoly which contributes to the pathogenesis of endodontic-periodontal lesions. This case report presents two unusual cases of Palatogingival groove. The patient in case 1 presented with a palatogingival groove in relation to left maxillary central incisor which was diagnosed radiographically as extending up to the apical third of the root. A combined endodontic- periodontal management of the tooth was done. The defect was restored with Mineral Trioxide Aggregate and the tooth was endodontically treated. The patient in case 2 presented with a similar defect which was diagnosed using spiral CT and treated by root canal therapy and intentional replantation.

Keywords

Endo-perio lesion; Intentional replantation; Mineral Trioxide Aggregate; Palatogingival groove; Spiral CT

J Odontol Res 2013;1(2):75-80

INTRODUCTION

Palatogingival groove is a developmental anomaly commonly associated with maxillary incisors, the clinical significance of which is related to the incidence of localized periodontitis with or without pulpal pathosis, depending on the depth, extent and complexity of the groove.[1] Prichard was the first to state that lingual grooves on maxillary incisor teeth are a pre-disposing factor to localized severe periodontal destruction.[2] These anomalies are difficult to diagnose and are usually spotted accidentally in routine clinical examination. In most cases, the periodontal symptoms are thought to be due to pulpal necrosis and an endodontic management alone is done. Such an incorrect diagnosis and treatment plan pave way for extraction of the tooth.[3,4]

The treatment of palatogingival groove depends upon the correct diagnosis and knowledge of the exact length and depth of the defect. The complex nature of the defect and its anatomic superimposition with the pulp chamber space complicates its detection using conventional radiograph alone.[4] This has lead to the introduction of an alternative imaging modality, spiral Computed Tomography (CT) to facilitate diagnosis of palatogingival groove. This article illustrates two different management approaches to the same problem of palatogingival groove.

Case Report 1

A healthy 24 year old male reported with discomfort and pain in relation to his left maxillary central incisor for the past 15 years. Patient's history revealed a habit of using bobby pins to relieve food impaction from the tooth. Clinical examination of tooth 21 (Federation Dentaire Internationale- FDI system of nomenclature) revealed a pinkish hue and loss of translucency on the labial surface. A radicular defect suggestive of palatogingival groove was seen on the palatal surface of 21 extending upwards into the gingival margin (Fig. 1A). Periodontal examination revealed localized recession with no periodontal pocket in relation to 21. The tooth exhibited grade I mobility. The tooth responded negatively to electric pulp testing. Radiographic examination (Fig. 1B) revealed an accentuated appearance of root canal in 21 which extended up to the apical third of the root, giving an insight into the extent of the groove. Mild widening of periodontal ligament space without any periapical pathosis was evident. A radiopaque object was seen in the root canal space suggesting the presence of a foreign body.

Correlating the clinical and radiographic findings, a provisional diagnosis of palatogingival groove in left maxillary central incisor associated with pulpal necrosis was made. Open curettage of the radicular defect, use of periodontal regenerative procedures and closure of the groove with Mineral Trioxide Aggregate (MTA), followed by root canal treatment of the tooth was planned.

Surgical flap elevation in relation to 21 showed the apical extent of the radicular groove and also its continuity with the root canal space (Fig. 1C). The foreign body (a piece of corroded and fracture bobby pin) was retrieved from the canal and root canal debridement was performed. The root surface was planed with curettes and the radicular groove was sealed with MTA (Pro Root, Dentsply/Tulsa Dental, Tulsa, Oklahoma, USA) (Fig. 1D). A wet cotton pellet was packed in the canal contacting the MTA before it was temporarily sealed. The bony defect was filled with a bone allograft (Puros cortical particulate allograft, Zimmer Dental Inc., Carlsbad, CA, USA). An absorbable collagen membrane (Biomend, Zimmer Dental Inc., Carlsbad, CA, USA) was placed over the graft and the flap was repositioned and sutured with 4-0 polyglactin 910 sutures (Vicryl, Ethicon, Inc., Piscataway, NJ). The patient was maintained on a 10-day doxycycline 100mg regimen along with prescription for Ibuprofen 600mg every 4 to 6 hours for 48 hours and chlorhexidine gluconate 0.12% rinse. Sutures were removed after a week and the post surgical healing was satisfactory. During this visit, root canal treatment of the tooth was completed (Fig. 1E). The patient was reviewed after 1 month and 6 months. The tooth was asymptomatic and no mobility was present. 2 year follow-up radiograph showed a satisfactory apical seal and no sign of osseous breakdown was present (Fig. 1F).

Case Report 2

A healthy 22 year old male reported with a complaint of discoloration and mobility in his left maxillary central incisor for the past 3 years. The patient had no history of trauma and complained of mild discomfort due to mobility of the tooth. On clinical examination, a discolored, mesially and labially inclined tooth no.21 (FDI nomenclature) was evident. The tooth exhibited grade II mobility. Soft tissue examination revealed an inflammed gingiva with a gingival swelling on the palatal aspect of left maxillary central incisor. Deep infrabony pockets were present in association with 21, while adjacent teeth were found to be periodontally healthy. A radicular groove was seen on the palatal aspect of the tooth starting from the cingulum and proceeding upwards into the gingival margin (Fig. 2A).

Radiographic examination revealed an enormous amount of bone loss associated with the tooth, but the radicular groove was not evident on the radiograph (Fig. 2B). Then the patient was subjected to spiral CT (GE Light Speed 3D-VCT, Bharat Scans, Chennai, India). The three-dimensional (3D) reconstructed images revealed a 5-6mm deep palatogingival groove, non-continuous with the root canal space and extending from the cingulum area upto the apical third of the root (Fig. 2C, 2D). Considering the questionable prognosis of the tooth, a decision of intentional replantation following root canal treatment of 21 and closure of the radicular defect with MTA was planned.

The tooth was extracted under local anesthesia. Root canal treatment was performed on the tooth while holding the crown portion with gauze. The radicular groove was sealed with MTA (Pro Root, Dentsply/Tulsa Dental, Tulsa, OK). The socket was curetted for any granulation tissue and irrigated. A bone allograft (Puros cortical particulate allograft, Zimmer Dental Inc., Carlsbad, CA, USA) was placed in the socket. The tooth was replanted in the socket and splinted with adjacent teeth using orthodontic wire and composite resin. The whole procedure was completed in 30 minutes so as to maintain the integrity of periodontal cells. A post operative radiograph was taken (Fig. 2E) immediately after the procedure. The patient was advised to take Ibuprofen 600mg 4 to 6 hour for 2 days and use chlorhexidine gluconate 0.12% rinse every time after meals for 3 days. The patient was reviewed after three days. The patient was asymptomatic without any pain or swelling. The splint was removed after three weeks. The patient was reviewed after 1 month and 6 months. At 1 year follow-up, the patient was still asymptomatic, but grade I mobility was observed in 21. A periapical radiograph was taken at that time which showed bone loss around 21 (Fig. 2F). During the 18- month recall of the patient, it was observed that mobility had progrssed to grade III stage and hence extraction of 21 was suggested to the patient. With the patient's informed consent, the tooth was extracted under local anesthesia. A fixed prosthodontic replacement of the missing 21 was recommended to the patient after complete healing of the extraction site.

DISCUSSION

Palatogingival groove / radicular groove is a dental anomaly occurring in regions of maxillary incisors.[5] It is described in literature as distogingival groove or radiculolingual groove. Exact etiology is not fully understood. Some clinicians believe that the groove represents the mildest form of dens invaginatus which implies that there is a minimal folding of enamel organ and Hertwig's root sheath during odontogenesis,[3] whereas the other investigators claim that this results from an attempt of the body to form another root on the affected tooth.[4]

Teeth with developmental malformations like palatogingival groove tend to fail to respond to treatment when they are associated with an invagination or vertical groove.[6] Variability in shape and size of this anomaly coupled with bacterial invasion may affect both the periodontium and the pulp. Pulp involvement may result from the introduction of bacterial toxins via channels that exist between the root canal system and the groove.[4] Dysplastic radicular dentin and numerous clefts are often encountered along the length of the defect, while in deeply invaginated cases there may be a groove with entrapped enamel within a blind cul de sac. For these anatomic reasons, the radicular groove is an ideal plaque trap for promoting periodontal breakdown and pulp necrosis.[7]

The basis of successful treatment outcome is an accurate diagnosis of the defect which presents a clinical challenge to the operator,[8] as in most of the cases the symptoms mimic a vertical root fracture or periodontal abscess or a combined endo-perio lesion. If a condition is purely periodontal, it can be diagnosed by probing the depth of the pocket which is usually tubular in form and localized to this area. The tooth will respond to pulp testing procedure unless in severe cases when the pulp gets infected.[6] On radiographic examination, a parapulpal line may be seen resembling vertical root fracture[3] and in severe cases, tear drop shaped radiolucency is also seen.[6] Radiographs taken at different angles may aid in diagnosis of this defect.[1]

All these factors indicate that the conventional radiography is not the imaging modality of choice in the detection of palatogingival groove and there is a need for developing an alternative imaging modality for diagnosis of this defect. This led to the introduction of CT in diagnostic endodontology. The earlier CT systems took longer time to scan and required

Figure 1

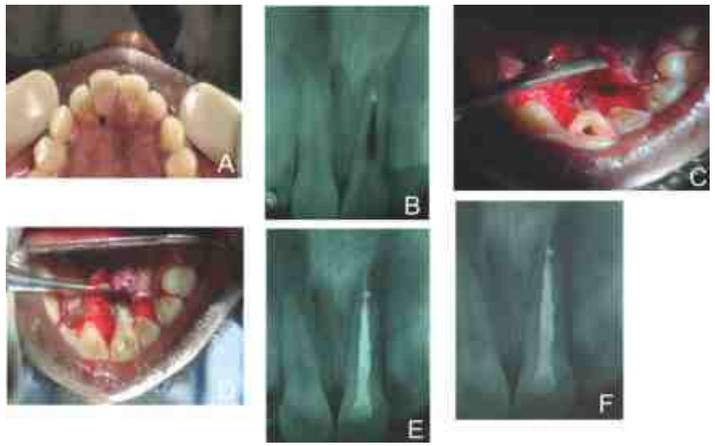

Figure 1-Images of case report1
Fig 1A- Pretreatment photograph showing radicular groove in the palatal surface of 21.
Fig 1B- Periapical radiograph of 21 showing an accentuated root canal and a radiopaque object suggestive of a foreign body.
Fig 1C- Surgical photograph showing the extent of the radicular groove upto the apical third of the root.
Fig 1D- Curettage of the radicular defect and sealing with MTA.
Fig 1E- Radiograph taken immediately after obturation of root canal in 21.
Fig 1F- 2 year follow-up radiograph showing an intact apical seal and a healthy periradicular area.

Figure 2

Figure 2- Images of case report 2
Fig 2A- Pretreatment image showing gingival swelling and radicular groove in the palatal aspect of 21.
Fig 2B- Pre-operative radiograph showing the osseous defect around 21. But the radicular groove is not visible.
Fig 2C- Spiral CT image of 21. Posterior view showing the extent of the radicular groove.
Fig 2D- Spiral CT image of 21. Lateral Oblique view.
Fig 2E- Radiograph taken immediately after replantation and splinting of 21.
Fig 2F- 1year follow-up radiograph showing progressive bone loss around 21.

higher radiation dose to produce an image of appreciable clarity. But with the introduction of spiral CT, scan time and radiation exposure have been greatly reduced.

In contrast to conventional CT systems, spiral CT offers the following advantages

1. Slice thickness of 0.625 mm, much lesser than the conventional system;

2. 73 % more area coverage/second (0.175 mm/second) thus reducing the scan time significantly;

3. A very high resolution (0.35 mm microvoxels).

With this high resolution even microcracks can be visualized on tooth surfaces. The other variants of CT available are: tuned aperture computed tomography (TACT), cone beam CT (CBCT), local CT, flat panel volume detector CT (FDVCT) and micro-CT.[9,10] From the day of its inception, radiation dose has remained the primary concern for limiting the usage of conventional CT to selected cases. With recent advancements in the field of radiology, spiral CT offers significantly less radiation exposure when compared to conventional CT. This is primarily due to the use of multiple X-ray sources and increased number of detectors/sensors which has led to a significant reduction in scan time.[10,11] Use of spiral CT for detection of vertical root fracture has been reported in literature.[12,13] However, its use in detection of palatogingival groove has not been reported frequently.

In the current case reports, the patient in Case 2 was subjected to spiral CT and 2D axial slices obtained were reconstructed three dimensionally with a volume rendering software as provided by the manufacturer. The CT images revealed a deep groove extending from the cingulum to the apical third of the root. There was no direct communication between the groove and the pulp.

Over the years, various treatment modalities have been tried and the prognosis depends upon the severity of periodontal problem, accessibility of the defect and the type of groove (shallow/deep, short/long).[14] In relatively shallow grooves the following treatment modalities have been proposed:

1. Placing an amalgam restoration in the groove[3,4]

2. Gingivectomy or apically repositioned flap[3]

3. Radiculoplasty along with sealing the groove with glass ionomer cement[8,15]

4. Surgical exposure and flattening of groove by grinding with high-speed diamond drill or fine stone with or without application of guided tissue regeneration[14]

Deep grooves present complex endo-perio problems. Combined treatment modality involving root canal therapy, elimination of groove, emdogain application and intentional replantation has been tried.[16] Intentional replantation has also been tried for periodontally compromised hopeless teeth.[17,18[A severe periodontal defect may be secondary to endodontic involvement as bacteria emanating from the infected root canal system may extend into the apical base of the fissure and progress coronally.[4] However, such a hypothesis cannot be applied to the cases presented here as the patients neither gave a history of trauma nor had the teeth been subjected to restoration.

MTA was chosen to seal the radicular groove in both the cases considering the well documented biocompatible nature of MTA that may induce cementum formation and its ability to regenerate periradicular tissue.[19] Also, its excellent sealing ability under[20] moist conditions was an essential requirement for the successful healing in these cases.

Intentional replantation of teeth is defined as the removal of a tooth and its almost immediate replacement in its socket, after obturating the canal apically while the tooth is out of its socket.[21] This procedure, however, should not be routine in dental practice and should only be considered as a last resort to save the tooth as there is a high probability for the occurrence of root ankylosis after replantation, with subsequent resorption of the tooth.[22]

On evaluation of the clinical symptoms, radiographic features and vitality tests, it was concluded that in case 1, the patient had a deep radicular groove communicating with the root canal space and in case 2, the groove was non-continuous with the root canal but presented with extensive bone loss and was considered periodontally compromised. Hence for case 1, open curettage, closure of the defect and combined endodontic - periodontal management were performed. For case 2, intentional replantation following root canal therapy and filling of the osseous defect with bone allograft were done. After 2 years of completion of treatment, Case 1 has responded well and is asymptomatic. But the progressive bone loss in case 2 resulted in failure of treatment inspite of an attempt to save the tooth.

REFERENCES

1. Pein-Chi W, Milton G, Chiu-Po C, Yuh-Ren J. Successful treatment of pulpo-periodontal combined lesion in a birooted maxillary lateral incisor with concomitant palato-radicular groove: A case report. J Periodontol 1999;70:1540-6.
2. Prichard, JS. Advanced periodontal therapy. Philadelphia: WB Saunders Co.,1965.
3. Lee KW, Lee EC, Poon KY. Palato-gingival grooves in maxillary incisors: A possible predisposing factor to localized periodontal disease. Br Dent J 1968;2:14-8.
4. Simon JHS, Glick DH, Frank AL. Predictable endodontic and periodontal failures as a result of radicular anamolies. Oral Surg Oral Med Oral Path Oral Radiol Endod 1971;31(6):823-6.
5. Cecilia MS, Lara VS, de Moraes IG. The palato-gingival groove: A cause of failure in root canal treatment. Oral Surg Oral Med Oral Path Oral Radiol Endod 1998;85:94-8.
6. Ilan R, Simon JHS. Diagnosis, prognosis and decision making in the treatment of combined periodontal-endodontic lesions. Periodontol 2000 2004;34:165-203.
7. Everett FG, Kramer GM. The disto-lingual groove in the maxillary lateral incisor: A periodontal hazard. J Periodontol 1972;43(6):352-61.
8. Jayashankara CM, Kala M. “Palatogingival groove”- An endodontic enigma. Journal of Dental Sciences and Research 2010;1(2):23-9
9. Hannig C, Dullin C, Hulsmann M, Heidrich G. Three dimensional, non-destructive visualization of vertical root fractures using flat panel volume detector computed tomography: An ex vivo in vitro case report. Int Endod J 2005;38:904-13.
10. Rachana D, Nadig P, Nadig G. The palatal groove: Application of computed tomography in its detection - A case report. J Conserv Dent 2007;10:83-8
11. Parks ET. Computed tomography applications for dentistry. Dent Clin North Am 2000;44(2):371-94.
12. Youssefzadeh S, Gahleitner A, Dorffner R, Bernhart T, Kainberger FM. Dental vertical root fractures: Value of CT in detection. Radiology 1999;210(2):545-9.
13. Nair MK, Nair UDP, Grondahl HG, Webber RL, Wallace JA. Effect of iterative restoration on the detection of artificially induced vertical radicular fractures by tuned aperture computed tomography. Oral Surg Oral Med Oral Path Oral Radiol Endod 2003;96:118-25.
14. Kerezoudis NP, Siskos GJ, Tsatsas V. Bilateral buccal radicular groove in maxillary incisors: Case report. Int Endod J 2003;36:898-906.
15. Hans MK, Srinivas RS, Shetty SB. Management of lateral incisor with palatal radicular groove. Indian J Dent Res 2010;21:306-8
16. Khalid AH, Jafar N, Simon, JHS, Samuel O, Ilan R. Successful treatment of a radicular groove by intentional replantation and emdogain therapy. Dent Traumatol 2004;20:226-8.
17. Demiralp B, Nohutcu RM, Tepe DI, Eratalay K. Intentional replantation for periondontally involved hopeless teeth. Dent Traumatol 2003;19:45-51.
18. Arun A, Bhandi S, Subhash TS . Palato-gingival groove- An enigma. International Journal of Contemporary Dentistry 2010;1(2).
19. Pitt Ford TR, Torabinejad M, McKendry DJ, Hong CU, Kariyawasam SP. Use of mineral trioxide aggregate for repair of furcal perforations. Oral Surg 1995;79:756-62.
20. Torabinejad M, Chivian N. Clinical applications of mineral trioxide aggregate. J Endod 1999;25(3):197-205.
21. Grossman LI. Endodontic practice. Philadelphia:Lea and Febiger, 1988:329-31.
22. Hayashi M, KinomotoY, Miura M, Sato I, Takeshige F, Ebisu S. Short-term evaluation of intentional replantation of vertically fractured roots reconstructed with dentin-bonded resins. J Endod 2002;28(2):120-4.

CASE REPORT

ECTODERMAL DYSPLASIA - A REVIEW AND CASE REPORT

Authors:
Archana A. Thomas[1],
Kumar Kavita Krishna[2],
Meera Gopalakrishnan[3]

[1]Reader, Department of Pedodontics and Preventive Dentistry, St. Gregorios Dental College, Chelad, Kothamangalam, Kerala, India.

[2]Senior Lecturer, Department of Pedodontics and Preventive Dentistry, St. Gregorios Dental College, Chelad, Kothamangalam, Kerala, India.

[3]Reader, Department of Conservative Dentistry and Endodontics, Indira Gandhi Institute of Dental Sciences, Nellikuzhy P. O., Kothamangalam 686 691, Kerala, India.

Address for correspondence:
Dr. Archana A. Thomas,
Reader,
Department of Pedodontics and Preventive Dentistry,
St. Gregorios Dental College, Chelad,
Kothamangalam, Kerala, India.
E mail: arcjon@gmail.com.

Abstract:

A 3 year old male child described in this report exhibited features of ectodermal dysplasia along with partial anodontia .The treatment attempted to improve his appearance and restore oral functions with fixed functional space maintainers. The results were a significant improvement in confidence, esthetics, speech and function of child and parental satisfaction. Also ability of child to improve dietary habits was noted. This article aims to provide the reader an insight into various modalities of managing child patients with ectodermal dyaplasia.

Keywords:

Ectodermal dysplasia; anhydrotic; hypodontia; anodontia; space maintainer.

J Odontol Res 2013;1(2):81-6

INTRODUCTION:

Ectodermal dysplasia is group of hereditary disorders characterised by developmental dystrophies of ectodermal derivatives[1]. Freire - Maia- Pinheiro have described 154 patterns of ectodermal dysplasias, divided them into 11 subgroups, and then classified them according to the involved structures.(hair,teeth,some or all of the sweat glands)[2]. It was first described by Thurnam[3] in 1848 and later in the 19th century by Darwin[4]. It is an X-linked recessive disorder[5]. The condition is thought to occur in 1-7 per 100000 live births[6]. Around 90% of cases are males and the complete syndrome does not occur in females[7]. The clinical findings in carrier females are the same as those in affected males. One third of the carriers appears healthy, another third of them is showing mild symptoms, and the last third exhibits significant symptoms, but often milder than the affected males (Sofaer et al. 1981)[8]. A much rarer form of anhidrotic ectodermal dysplasia inherited as an autosomal recessive trait has been described[9], where phenotypically, the features are indistinguishable from those of the X-linked form except that complete syndrome occurs in females[10]. It is characterized by a triad of signs comprising sparse hair, abnormal or missing teeth and inability to sweat. Anodontia or hypodontia is the most striking dental manifestation[11]. In severe hypodontia, there is lack of alveolar development with consequent protrusion and eversion of the lips[12]. Christ-Siemens-Touraine syndrome, also known as anhidrotic ectodermal dysplasia is characterized by partial or complete absence of sweat glands, hypotrichosis and hypodontia .

Disease name and synonyms

Ectodermal dysplasia anhidrotic (EDA)

Anhidrotic ectodermal dysplasia

Hypohidrotic ectodermal dysplasia (HED)

Christ-Siemens-Touraine syndrome

Incidence and inheritance pattern: The prevalence of EDA is unknown; however, the incidence in male is estimated at 1 in 100,000 births although the condition is usually overlooked in infants (Bergendal et al. 1998)[13]. This X-linked recessive disorder affects males and is inherited through female carriers. This carriers-incidence is probably 17.3 in 100,000 women (Sofaer 1981)[8]. (EDA) is the most common Ectodermal dysplasia (80%); it is characterized by hypoplasia of hair, teeth and sweat glands. (Mc Kusick, 1994)[14]. Since there is not a complete lack of sweat glands the term hypohidrotic is more adequate than anhidrotic. The anhidrotic hypohidrotic) ectodermal dysplasia is often inherited as an X-linked disorder (XLEDA). The differential diagnostic problem is the distinction of the autosomal recessive form of HED (AR-HED) from X-linked HED. AR-HED is considerably less common than XLHED. The clinical features are quite similar in both conditions but due to the different mode of inheritance AR-HED affects both males and females and the heterozygotes have no signs at all. For adequate genetic counseling it is thus important to recognize XLHED heterozygotes by dental examination and sweat tests. To distinguish between AR- and XL-forms, the HED diagnosis should be followed by careful family history for ectodermal manifestations both in male and female and by tests for heterozygote identification. The findings of equally affected males and females in single sibships, as well as the presence of consanguinity, support an autosomal recessive mode of inheritance (Munoz et al 1997)[15].

Case report :

A 3 year old boy was referred to the department of Pedodontics, St. Gregorios Dental College, Kothamangalam; with a chief complaint of pain and swelling in upper front teeth. Parents were also concerned as child just had upper primary canines, primary second molars apart from root stumps of primary central incisors in the upper arch and primary second molars in the lower arch.

On examination coronal portion of central incisors were lost due to caries and the root stumps were pulpally involved. Single sitting pulpectomies were carried out for the incisors as patient was already on medication with antibiotic and analgesic.

Subsequently after treatment parents raised their concerns over absence of teeth unlike his peers. The child himself was upset over joining school without teeth like other children at home. He presented facial features of scanty eyebrows, rounded nose, prominent chin, brittle and fine black hair, protruded lips, partial anodontia, loss of vertical dimension and anomalous development of alveolar ridges. The skin of his extremities was dry and wrinkled.

Radiographic findings:

OPG revealed the presence of upper molars, conical canines and root stumps of central incisors in the upper arch. Erupted mandibular second molars and mandibular primary canines embedded in the lower arch with half of root formation were seen.

Treatment done:

At the next visit crowns if 51, 61 were built up with composite with strip crowns, Preliminary impressions of upper and lower arches were made. OPG and lateral cephalogram were taken.

As the child was very young and lacking the dexterity needed to maintain a removable space maintainer, it was decided to give him fixed banded type of space maintainers for the time being with a lot of stress on the need for regular recall. Special trays were made and secondary impressions were made with rubber base impression material. Bands were fabricated on the upper and lower molars. Acrylic teeth were mounted on acrylic flown into the fixed space maintainer design.

This was cemented onto the patient's molars with luting GIC on the 3 rd visit. Patient and parents were happy with the esthetics, and restoration of masticatory function.

They are now on a 3 month recall visit program for the last one and a half years where the functional space maintainers on both arches are removed and cleared of residual food debris. On their last visit the lower primary canines were seen to erupt accordingly the arches were relieved of the acrylic component also to facilitate a self cleansing action.

As the child ages the fixed type of space maintainers will be changed to removable ones so as to give adequate rest to the periodontal tissues and maintain them in good health.

DISCUSSION:

Missing teeth or the delay in teething often starts to worry the parents and leads to the diagnosis of EDA in the second year of life (Pirinen et al. 1996). A dentist should not hesitate to radiographically examine a patient whose teeth have not erupted by the appropriate age in order to exclude EDA. The screening limit for the first tooth to erupt is 15 months (Pirinen et al. 1996)[16].

Ohno K and Ohmori reported cases of anodontia and the fabricating procedure of full dentures for a young child was described[17].

GerardKearns et al studied the feasibility of placing endosseous implants in children and adolescents with ectodermal dysplasia and to assess the position and stability of such implants during growth. This article reports on 6 subjects with long-term follow-up. There was no evidence that implant placement or prosthetic rehabilitation resulted in restriction of transverse or sagittal growth. They observed that maxillary implants placed in a partially dentate jaw became submerged because of adjacent alveolar development and required placement of a longer abutment. They concluded that endosseous implants can be successfully placed and can provide support for prosthetic restoration in patients with hereditary ectodermal dysplasia[18]

Third molars and maxillary lateral incisors are the most common congenitally missing teeth. Complete anodontia of both deciduous and permanent dentition is rarely reported. Açikgöz et al. reported the absence of all primary and permanent teeth except the bilaterally unerupted maxillary permanent canines. This shows that the permanent tooth can develop in the absence of its predecessor[12].

Even in the case of complete anodontia, the general facial growth pattern is normal in these children. This implies that the development of the jaw does not depend to the presence of teeth. Nevertheless, the alveolar process does not develop in the absence of teeth, and the vertical dimension is reduced, which explains the protuberant everted appearance of lips in these patients[19]. In this case, missing teeth were more in the mandible than in the maxilla. Therefore, the underdevelopment of alveolar process in mandible was more evident in clinical and radiographic features.

Alterations in bone structure, such as hyperdensity of medullary bone, have been found in mandibular symphysis area and other jaw locations of these

patients. Although changes in the alveolar bone can be related to oligodontia, changes in the bone structure seem to be tooth independent and suggest a direct effect of genetic defect on bone formation and/or remodeling in this syndrome[20].

If hypohidrosis is managed appropriately, the prognosis for most patients will be very good. Treatment of these children is protecting them from high temperature. In most cases, the preferred treatment option for dental disorders is a removable partial denture, which could also be associated with direct composite restorations. This allows the child to have adequate nutrition, normal appearance, and speech with significant psychosocial benefits. When child reaches teenage years, orthodontic treatment will prepare the mouth for a fixed partial denture or implants in future. In some patients, alveolar ridges are severely hypotrophic due to oligo- or anodontia. This can seriously affect a young person physically and psychologically. In these cases, augmentation of jaws by the use of bicortical corticocancellous bone blocks from hip and delayed implant placement seems to be a suitable treatment option. Immediate loading has also been applied successfully in patients with ectodermal dysplasia[20].

Broad treatment guidelines to the condition

The course of the treatment is to restore the function and the aesthetics of the teeth,normalise the vertical dimension and support the facial soft tissues. As long as there are no physical, psychological or social burdens, no treatment is necessary. Early placement of partial or full dentures is commonly recommended from the age of two or three years onwards. The denture must be periodically modified as alveolar growth; erupting teeth and rotational jaw growth, change both the alveolar, occlusal and basal dimensions. In children, breakage and even loss of removable prostheses is quite common. They have also a limited retention and stability, a fastened bone destruction of an already hypoplastic alveolar process and the middle of the upper jaw is covered and so it blocks the sutural growth. For this reason, in young children we prefer a treatment with crowns and bridges. Prior to that it is generally advantageous to modify the crowns of the existing teeth with direct or indirect composite crowns. When conical anterior teeth are crowned the appearance of the child is very much normalised. Restoration of facial height improves both facial aesthetics and speech[21].

CONCLUSION:

Dentists are often the first who diagnose these patients. Therefore, they should be aware of the clinical manifestations of this syndrome. This will be helpful in proper diagnosis, early interventions, and appropriate therapies for these patients.

As children with anodontia present with an insufficient amount of alveolar bone, implantation reconstruction surgery is subjected to a greater risk of failure in comparison to more conservative prosthetic treatment. To restore function as well as esthetics bonded space maintainers were used in this patient as a management modality. It is essential to provide continous evaluation of such patients to monitor the state of the alveolar ridge and accommodate erupting teeth. The main aim of the treatment was to improve psychological development and to promote better functioning of the stomatognathic system.

Fig 1: Pre Operative facial Photograph showing scanty eyebrows, rounded nose, prominent chin, brittle and fine black hair, protruded lips and loss of vertical dimension

Fig 2 : Wrinkled appearance of hands

Fig 3: Dry appearance of legs and feet

Fig 4: Pre Operative Upper Jaw with primary incisor root stumps, conical canines and second molars only.

Fig 5: Pre Operative lower jaw showing primary canines and second molars only

Fig 6: OPG shows presence of tooth buds of permanent first molars in all four quadrants along with the teeth clinically present.

Fig 7 : Post operative view of fixed, banded space maintainers

Fig 8: Post Operative view of face

Fig 9 : Lower space maintainer modified for eruption of canines

REFERENCES:

1. Clouston H.R. The Major forms of hereditary Ectodermal Dysplasia. The Canadian Medical Association Journal. Vol 40; (1) 1939:1-7
2. 2. Pinheiro N,Freire-Maia.Ectodermal dysplasias: A Clinical classification and a Casual Review. Am J Med Genet1994;53:153-62
3. Thurnam J. Two cases in which the skin, hair and teeth were very imperfectly developed. Proc RM Chir Soc 1848;31:71-2.
4. Darwin C. The variac, ns of animals and plants under domestication. 2nd edn. John Murray, London 1875 P 319.
5. Reed WB, Lopez DA, Landing B. Clinical spectrum of anhidrotic ectodermal dysplasia. Arch Dermatol 1970;102:134-7.
6. Shashi Bala et al .Prosthetic rehabilitation of a child suffering from Ectodermal dysplasia with complete anodontia. Int J Clin Pediatr Dent 2012;5(2):148-50
7. Gazanfar Ali, Manoj Kumar, R Verma, V Khajuria, MB Wadhwa. Anhidrotic ectodermal dysplasia (christ - seimens - touraine syndrome) - case report with a review.Indian J Med Sci 2000;54:541-4
8. Sofaer J.A.: A dental approach to carrier screening in X-linked hypohidrotic ectodermal dysplasia. J.Med. Genet. (1981) 18:459-460
9. Verbov J. Hypohydrotic (or anhidrotic) ectodermal dysplasia. An appraisal of diagnostic methods, Br J dermatol 1970;83:341-8.
10. Gorlin RJ, old T, Anderson VE. Hypohidrotic ectodermal dysplasla in females. A critical analysis and argument for genetic heterogenity. Z Kinderheilk 1970;108:1-11.
11. Kerr CB, Wells RS, Cooper KE. Gene effect in carriers of anhidrotic ectodermal dysplasia. J Med Genet 1966;3:169-76.
12. Açikgöz A, Kademoglu O, Elekdag-Türk S, Karagöz F. Hypohidrotic ectodermal dysplasia with true anodontia of the primary dentition. *Quintessence International*. 2007;38(10):853–858.
13. Bergendal B., Koch G., Kurol J., Wänndahl G.:Consensus conference on ectodermal dysplasia with special reference to dental treatment. The Institute for Postgraduate Dental Education,Jönköping, Sweden (1998)
14. McKusick V.A.: Mendelian inheritance in man. The John Hopkins University Press, Baltimore, 11th edition (1994)
15. Munoz F., Lestringant G., Sybert V., *et al*.Definitive evidence for an autosomal recessive form of hypohidrotic ectodermal dysplasia clinically indistinguishable from the more common X-linked disorder. Am. J. Hum. Genet. (1997)61:94-100
16. Pirinen S. In: Meurman, Murtomaa, LeBell, Autti,Luukkanen (eds): Therapia Odontologica.Academica Kustannus Oy, Helsinki (1996) p. 414
17. Ohno K, Ohmori I. Anodontia with hypohidrotic ectodermal dysplasia in a young female: a case report. Pediatr Dent. 2000 Jan-Feb; 22(1):49-52.
18. G Kearns, A Sharma, D Perrott, B Schmidt. Placement of endosseous implants in children and adolescents with hereditary ectodermal dysplasia. Oral Surg Oral Med Oral Pathol Oral Radiol Endod 1999;88:5-10.
19. Lesot H, Clauss F, Manière MC, Schmittbuhl M. Consequences of X-linked hypohidrotic ectodermal dysplasia for the human jaw bone. *Frontiers of Oral Biology*. 2009;13:93-9.
20. Mokhtari S, Mokhtari S, Lotfi A.Christ-Siemens-Touraine Syndrome: A Case Report and Review of the Literature. Case Rep Dent. 2012; Published online 2012 November 29. doi: 10.1155/2012/586418
21. Mortier K, Wackens G. Ectodermal Dysplasia Syndrome. Orphanet Encyclopedia. September 2004. http://www.orpha.net/data/patho/GB/uk-ectodermal-dysplasia-anhidrotic.pdf

CASE REPORT

INVERTED AND SEVERELY DILACERATED MESIODENS PREVENTING ERUPTION OF CENTRAL INCISOR: A CASE REPORT

Authors:
Sahana Srinath[1],
Srinath SK.[2],
Vishwanath Sk[3],
Ritu Singh[4]

[1]Associate Professor, Department of Oral Pathology and Microbiology, Government Dental College and Research Institute, Bangalore, Karnataka, India.

[2]Associate Professor, Department of Pediatric Dentistry, Government Dental College and Research Institute, Bangalore, Karnataka, India.

[3]Associate Professor, Department of Prosthodontics, Government Dental College and Research Institute, Bangalore, Karnataka, India.

[4]Post Graduate student, Department of Pediatric Dentistry, Government Dental College and Research Institute, Bangalore, Karnataka, India.

Address for correspondence:
Dr. Sahana NS, Associate Professor, Department of Oral Pathology and Microbiology, Government Dental College and Research Institute, Bangalore, Karnataka, India.
E mail: drsahanans@gmail.com.

ABSTRACT

A ten year old boy came with a chief complaint of unerupted permanent maxillary right central incisor. Deciduous right central and lateral incisors were retained. Radiographic examination revealed an inverted and dilacerated mesiodens with the root bent over the incisal surface of the right central incisor preventing its eruption. An occlusal radiograph and radiographs using shift cone technique were taken to determine the position of the mesiodens. Extraction of retained deciduous incisors was done, followed by surgical removal of mesiodens to allow unhindered eruption of the central incisor.

Key words: Tooth, Supernumerary, Unerupted

J Odontol Res 2013;1(2):87-92

INTRODUCTION

Supernumerary teeth, or hyperdontia, refer to the teeth that form in addition to the normal dental formula.[1, 2] They may occur in any region of the dental arch, in the maxilla or in the mandible, singly or in multiples, unilaterally or bilaterally, erupted or unerupted. They can be associated with a syndrome or they can be found in non-syndromic patients.[3,4]

The reported prevalence of supernumerary teeth ranges from 0.2% to 0.8% in the deciduous dentition, and ranges from 0.5% to 5.3% in the permanent dentition with geographic variations.[4,5] The incidence of supernumerary teeth is usually higher in males than in females. The reported male to female ratio was between 1.18:1 to4.5:1.[4,6] The most common supernumerary teeth are mesiodens, which occur between the maxillary central incisors.[7] More rarely, they can be located in the premolarand distomolar regions, and appear as supernumerary premolars or supernumerary fourth and fifth molars.[8]Supernumerary premolars constitute proximately 10% of the total supernumerary cases, and almost 75% of those are in the mandible.[9,10] It was reported that 76%–86% non-syndromic cases have only one supernumerary tooth, and 12%–23% cases have two supernumerary teeth.[3,6] Only 1% of non-syndromic cases have multiple supernumerary teeth, which occur most frequentlyin the mandibular premolar area, followed by the molar and the anterior regions, respectively.[3,11,12] Supernumerary teeth in the deciduous dentition are usually normal or conical shaped, whereas supernumerary teeth in the permanent dentition can exhibit various shapes. They may have normal morphology or may be rudimentary and miniature with little or no resemblance to the other teeth. Based on their morphology, supernumerary teeth are classified into four types, including conical type, tuberculate type, supplemental teeth, and odontomas.[13] The most common supernumerary teeth are small conical peg-shaped with root development at the similar stage or ahead of that of adjacent teeth. They usually develop in the anterior maxilla as mesiodens. Tuberculate supernumerary teeth are large barrel shaped with multiple cusps or tubercles. Their root development is delayed compared to that of adjacent teeth. They are mostly found unerupted in the palatal aspect of the maxillary central incisors, and this can cause the impaction of permanent maxillary incisors.[14,15]Supplemental teeth are duplications of teeth in the normal dentition with essentially normal size and shape, and they are usually found at the end of a tooth series. The most common supplemental tooth is the permanent maxillary lateral incisor, but supplemental premolars and molars were also reported. The majority of supernumerary teeth found in the primary dentition are of the supplemental type. They usually erupt with normal morphology and alignment, and often appear as a supplemental lateral upper incisor.[4,13] This may cause underreported and low prevalence of supernumerary teeth in the primary dentition.[2] There are special cases exhibiting permanent supernumerary teeth developing as supplemental teeth and forming after the permanent teeth. These are thought to represent a third dentition, best known as manifestations of cleidocranialdysplasia. Odontoma was listed as the fourth category of supernumerary teeth.[13] Some supernumerary teeth are just impacted in the jaw with no obvious adverse effects. They were usually identified incidentally during radiographic examinations for some other reasons.[10,11,12] However, the development of some supernumerary teeth can cause a broad range of complications, including retained or delayed eruption of permanent teeth, diastemas, displacement, rotation, crowding, root resorption, periodontal lesions, or pulp necrosis of adjacent teeth. They can also cause dentigerous (odontogenic) cyst, and the presence of unerupted supernumerary teeth may compromise tooth implantation as well as alveolar bone grafting in patients with cleft palate.[3,4,7,13,15,16]

The term 'dilaceration' refers to an angulation or a sharp bend or curve, in the root or crown of a formed tooth (Latin: *dilacero* = tear up).[17] The term was first used by Tomes and referred to as the 'forcible separation of the cap of the developed dentine from the pulp in which the development of dentine is still progressing.[18] The condition is thought to be due to trauma during the period in which the tooth is forming, with the result that the position of the calcified portion of the tooth is changed and the remainder of the tooth is formed at an angulation. The curve or bend can be anywhere along the length of the tooth, sometimes at the cervical portion, at other times midway along the root or even just at the apex of the root, depending on the extent of root formed at the time of injury. Presented here is a rare case of severe dilaceration of an impacted, inverted supernumerary toothpreventing eruption of permanent central incisor.

Case Report

A 10 years old boy came to the department of Pedodontics And Preventive Dentistry, Government Dental College And Research Institute Bangalore, with a chief complaint of unerupted permanent maxillary right central incisor [Figure 1].

On clinical examination right deciduous central and lateral incisors were found to be retained and left lateral incisor had preshedding mobility. Intra oral periapical radiograph revealed impacted right central incisor and an inverted and dilacerated mesiodens in the midline [Figure 2]. An occlusal radiograph and two intra oral periapical radiographs using SLOB rule were taken to determine the position of mesiodens[Figure 3,4]. As can be appreciated by the radiographs [figure4] when the tube head was shifted distally, mesiodens also shifted distally which suggests that mesiodens was palatally placed.

Maxillary occlusal radiograph clearly reveals the presence of mesiodens with severe dilacerations of almost 90^0 at the middle third of the root. Though the crown of the supernumerary was inverted, the long axis of the crown was parallel to the long axis of the unerupted permanent central incisor, however, with 90^0dilaceration, the dilacerated root was bent over the incisal edge of the unerupted tooth, hindering the eruption of permanent central incisor [Figure 3].

There was no relevant medical and family history and the child was otherwise healthy and not associated with any syndrome.

After a detailed examination, the decision was made to extract the retained deciduous incisors followed by extraction of mesiodens under local anaesthesia.

Nasopalatine nerve block and infraorbital nerve blocks on both sides were given. A full thickness palatal flap from canine to canine was raised.Right central incisor was visible after flap was elevated.Palatal bone was removed using airotorhandpiece under continuous saline irrigation. Periosteal elevator was used to elevate the tooth once the crown of the tooth was visible. Since the tooth was dilacerated extensive bone removal was required. Once the tooth was mobile in its socket it was extracted using extraction forceps [Figure 5]. Tooth was severly dilacerated and was approximated 1.4cm in size [Figure 6]. Surgical site was irrigated with 1% betadine and normal saline. Sutures were placed and patient was recalled after 5 days.

After 5 days sutures were removed. Surgical site was irrigated with normal saline and 1% betadine. Incisal tip of permanent right central incisor was visible as the tooth started erupting within this short time period.

DISCUSSION

The first report of supernumerary teeth appeared between AD 23 and 79. Most supernumerary teeth are isolated cases, although some may be familial inherited and some may be syndrome associated events.[3] The etiology of supernumerary teeth is still uncertain. A number of theories have been postulated to try to explain their presence, including atavism (evolutionary throwback), tooth germ dichotomy, hyperactivity of the dental lamina, and genetic and environmental factors.[19,20] The atavism or phylogenetic theory suggested that the occurrence of supernumerary teeth is a regression to the extinct ancestral tissues or anthropoids. This theory is based on the phenomena that ancestor mammals have more teeth with three incisors, one canine, four premolars, and three molars in each quadrant of the jaw.[21,22] The teeth of common modern mammals belong to these four tooth families. It is generally thought that during evolution, the total number of teeth per dentition decreased (from polyodonty to oligodonty) and the generations of teeth were also reduced (from polyphyodonty to diphyodonty or monophyodonty); whereas the morphology of teeth became more complex (from homodonty to heterodonty). Over the course of evolution, the teeth in placental mammals tend to disappear in an order that is opposite to the order of their eruption.[23] The tooth germ dichotomy theory proposed that during early tooth development, the dental lamina was divided into two parts of equal or different size, thus giving rise to two teeth with similar size, or one normal tooth and one dysmorphic tooth.[13,24,25] Hovorakova et al. analyzed the development of

Figure 1. Unerupted permanent right central incisor with retained deciduous incisors

Figure 2. IOPA showing inverted and dilacerated mesiodens

Figure 3. Maxillary occlusal radiograph showing inverted and dilacerated mesiodens hindering eruption of permanent central incisor

Figure 4. IOPA radiographs taken using SLOB rule to determine position of mesiodens

Figure 5. Empty extraction socket after extraction of mesiodens. Note palatally placed right central incisor.

Figure 6. Dilacerated Mesiodens of 1.4 cm

deciduous upper lateral incisor in human embryos using serial sections and computer-aided 3D reconstructions, and found that deciduous upper lateral incisors originate from the fusion of two dental epithelial thickenings, which were separated by a groove at the formal fusion site of the medial nasal and maxillary processes. Later, these two dental epithelial thickenings fused together and formed a continuous dental lamina, from which the deciduous upper lateral incisor develops.[24] Any disturbance causing cleft or incomplete fusion of the dental epithelial thickenings can result in the formation of supernumerary teeth. This may explain why the supernumerary upper lateral incisor often appears in the deciduous dentition, and in the conditions of cleft palate and cleft lip.[4]Hyperactivity of the dental lamina is another widely accepted theory.[3,1,19,20,24,26,28,29,30] Primary dental lamina (odontogenic band) is the thickening of oral ectoderm forming during the initiation stage of deciduous teeth and it gives rise to the deciduous dentition. During the cap or bell stage of deciduous tooth development, successional dental lamina forms from the lingual or posterior aspect of deciduous tooth enamel organ. It later elongates under the oral epithelium and buds into the jaw mesenchyme forming the successional (permanent) tooth or the posterior molar teeth.[31] Once the crown of the permanent tooth has formed, the dental lamina undergoes programmed cell death and degenerates. Residues of un-degenerated dental lamina epithelial cells may cause eruption cysts,[32] while overproliferation or prolonged survival of dental lamina epithelial cells may cause supernumerary tooth formation.[3,31,32] Heredity is also believed to be an important factor. Supernumerary teeth occur more commonly in the relatives of affected patients than in the general population.[21,33,34,35,36]

In the present case, Impaction of maxillary right central incisor was attributed to the presence of dilacerated mesiodens, and this has been observed in earlier reports.[37]

CONCLUSION:

Presence of an inverted, impacted, dilacerated mesiodens was associated with abnormal impaction of permanent central incisor. Supernumerary teeth should be extracted as early as possible.

REFERENCES

1. Cobourne MT, Sharpe PT. Making up the numbers: The molecular control ofmammalian Dentalformula.Semin Cell DevBiol 2010; 21:314-4.
2. Fleming PS, Xavier GM, DiBiase AT, Cobourne MT. Revisiting thesupernumerary: The epidemiological and molecular basis of extra teeth. BrDent J.2010;208:25-30.
3. Diaz A, Orozco J, Fonseca M. Multiple hyperodontia: Report of a case with 17 supernumerary teeth with non syndromic association. Med Oral Patol Oral CirBucal. 2009;14:E229-31.
4. Ferres-Padro E, Prats-Armengol J, Ferres-Amat E. A descriptive study of 113unerupted supernumerary teeth in 79 pediatric patients in Barcelona. Med OralPatol Oral Cir Bucal. 2009;14:E146-52.
5. Fardi A, Kondylidou-Sidira A, Bachour Z, Parisis N, Tsirlis A. Incidence ofimpacted and supernumerary teeth-a radiographic study in a North Greekpopulation. Med Oral Patol Oral Cir Bucal. 2011;16:e56-61.
6. Fernandez Montenegro P, Valmaseda Castellon E, BeriniAytes L, Gay EscodaC. Retrospective study of 145 supernumerary teeth. Med Oral Patol Oral Cir Bucal 2006;11:E339-44.
7. Hyun HK, Lee SJ, Lee SH, Hahn SH, Kim JW. Clinical characteristics andcomplications associated with mesiodentes. J Oral Maxillofac Surg.2009;67:2639-43.
8. Kokten G, Balcioglu H, Buyukertan M. Supernumerary fourth and fifth molars:A report of two cases. J Contemp Dent Pract 2003;4:67-76.
9. Hyun HK, Lee SJ, Ahn BD, Lee ZH, Heo MS, Seo BM, Kim JW.Nonsyndromic multiple mandibular supernumerary premolars. J Oral MaxillofacSurg 2008;66:1366-9.
10. Kawashita Y, Saito T. Nonsyndromic multiple mandibular supernumerary premolars: A case report. J Dent Child (Chic) 2010;77:99-101.
11. Inchingolo F, Tatullo M, Abenavoli FM, Marrelli M, Inchingolo AD, GentileM, Inchingolo AM, Dipalma G. Non-syndromic multiple supernumeraryteeth in a family unit

with a normal karyotype: Case report. Int J Med Sci2010;7:378-84.

12. Yague-Garcia J, Berini-Aytes L, Gay-Escoda C. Multiple supernumerary teethnot associated with complex syndromes: A retrospective study. Med Oral Patol Oral Cir Bucal 2009;14:E331-6.
13. Garvey MT, Barry HJ, Blake M. Supernumerary teeth- An overview ofclassification, diagnosis and management. J Can Dent Assoc 1999;65:612-6.
14. Backman B, Wahlin YB. Variations in number and morphology of permanentteeth in 7-year-old Swedish children. Int J Paediatr Dent 2001;11:11-7.
15. Yassin OM, Hamori E. Characteristics, clinical features and treatment ofsupernumerary teeth. J ClinPediatr Dent 2009;33:247-50.
16. Giancotti A, Grazzini F, De Dominicis F, Romanini G, Arcuri C.Multidisciplinary evaluation and clinical management of mesiodens. JClinPediatr Dent 2002;26:233-7.
17. Shafer WG, Maynard KH, Bernet ML. Oral Pathology. W.B.Saunders Co: Philadelphia;1993.p.40
18. Tomes J. Acourse of lecture on dental physiology and Surgery:London; 1848.Quoted by Mathis.
19. PrimoschRE.. Anterior supernumerary teeth-Assessment and surgical intervention in children. Pediatr Dent 1981;3:204-15.
20. Saarenmaa L. 1951. The origin of supernumerary teeth.ActaOdontolScand 9:293-303.
21. Babu V, Nagesh KS, Diwakar NR. A rare case of hereditary multiple impacted normal and supernumerary teeth. J ClinPediatr Dent 1998;23:59-61.
22. Osborne JW. Morphognetic gradients: Fields versus clones. In: Butler PM, Joysey KA, editors.Development, function and evolution. London: Academic Press. 1978;pp 171-201.
23. Koussoulakou DS, Margaritis LH, Koussoulakos SL. A curriculum vitae of teeth: Evolution, generation, regeneration. Int J BiolSci 2009;5:226-43.
24. Liu JF. Characteristics of premaxillary supernumerary teeth: A survey of 112 cases. ASDC J Dent Child 1995;62:262-5.
25. Taylor GS. Characteristics of supernumerary teeth in the primary and permanent dentition. Dent Pract Dent Rec 1972;22:203-8.
26. Munne PM, Felszeghy S, Jussila M, Suomalainen M, Thesleff I, Jernvall J. Splitting placodes: Effects of bone morphogenetic protein and Activin on the patterning and identity of mouse incisors. EvolDev 2010;12:383-92.
27. Hovorakova M, Lesot H, Peterkova R, Peterka M. Origin of the deciduous upper lateral incisorand its clinical aspects. J Dent Res 2006;85:167-71.
28. Foley MF, Del Rio CE. Supernumerary teeth.Report of a case. Oral Surg Oral Med Oral Pathol 1970;30:60-3.
29. Hattab FN, Yassin OM, Rawashdeh MA. Supernumerary teeth: report of three cases and review of the literature. ASDC J Dent Child 1994;61:382-93.
30. Rajab LD, Hamdan MA. Supernumerary teeth:Review of the literature and a survey of 152 cases.Int J Paediatr Dent 2002;12:244-54.
31. Zilberman Y, Malron M, Shteyer A. Assessment of 100 children in Jerusalem with supernumerary teeth in thepremaxillary region. ASDC J Dent Child 1992;59:44-7.
32. Jarvinen E, Tummers M, Thesleff I. The role of the dental lamina in mammalian tooth replacement. J ExpZool B MolDevEvol 2009;312B:281-91.
33. Cohen RL. Clinical perspectives on premature tooth eruption and cyst formation in neonates.PediatrDermatol 1984;1:301-6.
34. Becker A, Bimstein E, Shteyer A. Interdisciplinary treatment of multiple unerupted supernumerary teeth. Report of a case. Am J Orthod 1982;81:417-22.
35. Gallas MM, Garcia A. Retention of permanent incisors by mesiodens: A family affair. Br Dent J 2000;188:63-4.
36. Mercuri LG, O'Neill R. Multiple impacted and supernumerary teeth in sisters. Oral Surg Oral Med Oral Pathol 1980;50:293.
37. Prabhu NT, Rebecca J, Munshi AK. Mesiodens in theprimary dentition-a case report. J Indian SocPedodPrev Dent.1998 Sep;16(3):93-5.

CASE REPORT

REPAIR OF FURCAL PERFORATION WITH MINERAL TRIOXIDE AGGREGATE: A CASE REPORT

Authors:
Nevin Thomas Bj[1],
KC Ponnappa[2],
Meera Gopalakrishnan[3],
Dexton Antony Johns[4]

[1]Senior Lecturer, Department of Conservative Dentistry and Endodontics, Indira Gandhi Institute of Dental Sciences, Nellikuzhy P. O., Kothamangalam 686 691, Kerala, India.

[2]Professor and Head, Department of Conservative Dentistry and Endodontics, Coorg Institute of Dental Sciences, K. K. Campus, Magula, Virajpet 571 218, Karnataka, India.

[3]Reader, Department of Conservative Dentistry and Endodontics, Indira Gandhi Institute of Dental Sciences, Nellikuzhy P. O., Kothamangalam 686 691, Kerala, India.

[4]Senior Lecturer, Department of Conservative Dentistry and Endodontics, Government Dental College, Medical College P. O., Calicut 673 008, Kerala, India.

Address for correspondence:
Dr. Nevin Thomas BJ,
Senior Lecturer, Department of Conservative Dentistry and Endodontics, Indira Gandhi Institute of Dental Sciences, Nellikuzhy P. O., Kothamangalam 686 691, Kerala, India.
E mail: drnevin4you@yahoo.com.

ABSTRACT

Mineral Trioxide Aggregate is a material developed for endodontics that appears to be a significant improvement over other materials for procedures in bone. It is the first restorative material that allows for the overgrowth of cementum and the regeneration of periodontal ligament. The present case report illustrates the use of MTA in treating a case of perforation in the furcation area with long term follow up, that shows repair of the perforation defect and regeneration of the lost periodontium in the furcation area.

Key words: Mineral Trioxide Aggregate, furcation, perforation.

J Odontol Res 2013;1(2):93-6

INTRODUCTION

A common iatrogenic error in endodontic and restorative treatments is accidental perforation of the roots or the pulp chamber floor. Such perforation may occur during nonsurgical root canal treatment or during preparation for a variety of restorative procedures.[1] The prognosis may be questionable if treatment involves a lesion occurring at the level of the radicular furcation as prognosis also depends on the level of the furcation, but the prognosis is usually good if the problem is diagnosed correctly and treated with a material having suitable sealing ability and bio compatibility.[1]

Although use of Mineral Trioxide Aggregate (MTA) has been reported for several different endodontic treatments, the literature on its success in cases of furcal perforation is limited. This article describes a case in which MTA was used to repair furcation perforation which illustrate the potential benefits of MTA and its relative ease of use for management of perforation.

Case Report

A 36-year-old female patient was referred with accidental furcal perforation, which had occurred during access preparation for root canal treatment of tooth 46. The furcal perforation was confirmed by periapical radiography of tooth 46, which revealed osseous breakdown at the furcation (Fig 1). Several treatment options were discussed with the patient which included extraction, bicuspidization and nonsurgical repair of the perforation with MTA. The patient never wanted to extract her tooth and opted for root canal treatment along with repair of the perforation with MTA. Shaping and cleaning of the root canal was completed by hybrid technique (Fig 2), and the pulpal chamber was then irrigated with 3% sodium hypochlorite with precaution to prevent extrusion, to control hemorrhage and to allow visualization of the perforation. Cotton pellets moistened in saline were placed in orifices of the root canals, and the perforation was sealed with Pro-Root MTA (Maillefer, Dentsply, Switzerland) mixed with sterile saline, as suggested by the manufacturer. The MTA was covered with a cotton pellet moistened with distilled water and Cavit temporary restoration material (3M ESPE, St. Paul, Minn.). Two days after placement of MTA at the perforation, the patient underwent root canal treatment without complications and the access cavity was restored with composite (Fig 3). At the 15-day follow-up, the patient was asymptomatic with no signs of inflammation or sinus tract. Three months after the treatment, there was radiographic evidence of bone formation adjacent to the MTA. At the last check-up, 6 months after treatment, radiography showed complete osseous healing at the apex and the furcation (Fig. 4).

DISCUSSION

Iatrogenic perforations in the radicular furcation area is a common mishap that occurs during access preparations especially in teeth with calcified pulp chambers, due to which the tooth have to undergo extraction. But nowadays several materials have been used to repair furcation perforations, including zinc oxide-eugenol cements and its modifications like IRM and Super-EBA, glass ionomer cement, composite resins, resin-glass ionomer hybrids, and mineral trioxide aggregate (MTA).[2]

MTA materials are derived from Portland cement parent compound and have been demonstrated to be biocompatible endodontic repair materials, with its biocompatible nature strongly suggested by its ability to form hydroxyapatite when exposed to physiologic solutions. MTA materials provide better microleakage protection than traditional endodontic repair materials using dye, fluid filtration, and bacterial penetration leakage models

A successful repair will result in the reattachment of the periodontal ligament. To allow healing, a perforation repair material must provide a leak proof seal to ensure that contaminants within the tooth are unable to reach the periodontal ligament and vice versa. The material must be biocompatible and must be strong enough to withstand apical pressures. Mineral Trioxide aggregate has been recommended for the treatment of furcation perforations.[3] Pro-Root MTA (Maillefer, Dentsply, Switzerland) is composed of 75% Portland cement, 20% bismuth oxide and 5% dehydrated calcium sulfate.[4] MTA is difficult to manipulate because of its granular consistency, slow setting time and looseness.[5] Contamination of the blood should be avoided when using this type of material, as such contamination can reduce the retention capacity of the MTA.[6] At present, all treatment options are considered to have a guarded prognosis.[7] When evaluating a perforated tooth, 4 variables should be considered: level, location, size and shape, and time.[8]

1. Level. Perforations can occur in the coronal, middle, or apical one third of the tooth. The prognosis of radicular perforations of the apical and middle third is much better than perforations of the coronal third or of the pulp chamber floor of multirooted teeth.[9,10]

2. Location. Perforations which occur circumferentially on the buccal, lingual, mesial, or distal aspects of the roots. This is an important consideration if surgical access is considered, while it is not as important in the case of nonsurgical retreatment.

3. Size and shape. The dimension and shape of the perforation primarily influence the establishment of a good seal. The larger the bur causing the perforation, the bigger the area to seal. Furthermore, lateral perforations are never round, but are elliptical in shape, since the bur meets the canal wall at a 45° angle.

Finally, the perforating cavity has no taper, and this makes it difficult to establish a good apical seal without disturbing the surrounding periodontium.

4. Time. Perforations create an inflammatory reaction in the adjacent tissues, and consequently a loss of attachment. Therefore, to discourage further loss of attachment and periodontal breakdown, perforations should be sealed as soon as possible, preferably during the same appointment they occur.

To achieve success following treatment of a perforation, the treated tooth must meet the following requirements:[11]

Absence of symptoms, such as spontaneous pain, or pain on palpation or percussion

Absence of excessive mobility

Absence of a communication between the perforation and the gingival crevice

Absence of a fistula

The tooth must be functional

Absence of radiographic signs of demineralization of the bone adjacent to the perforation

Thickness of the periodontal ligament adjacent to the repair material should be no more than double the thickness of the surrounding ligament. If any one of these criteria cannot be met, therapy cannot be considered as a success.[11]

The good outcomes of MTA were obtained because it is the material that is not affected by moisture or blood contamination. MTA sets only in contact with moisture. It is a hydrophilic material and can be considered as the best material to seal perforations [12]

Fig 1 Periapical image of tooth 46 showing inadvertent furcal perforation, caused by drilling during access preparation for root canal treatment.

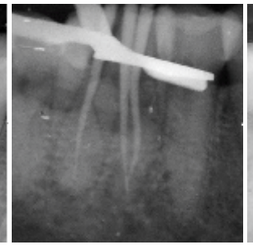

Fig 2 Tooth 46 after Shaping and cleaning

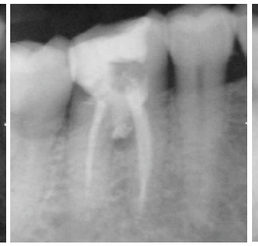

Fig 3 Post operative after placing Mineral trioxide aggregate (MTA) and obturation

Fig 4 Bone formation is visible at 6-month follow-up.

CONCLUSION

Perforations represent pathologic or iatrogenic communications between the root canal system and the periodontal attachment apparatus. Prevention is the most important factor to avoid accidents during endodontic therapy. Treating a perforation may often require a multidisciplinary approach in order to establish an appropriate treatment plan, and the clinicians must decide whether to extract the tooth or treat it with a nonsurgical and/or surgical approach. The prognosis of perforated teeth is better today than it was in the past, and this is due to the improved vision provided by the operating microscope as well as the use of biocompatible materials such as MTA. With this approach, perforations can be more predictably repaired without surgery, thus reducing the need for invasive and more costly procedures.

REFERENCES:

1. Tsesis I, Fuss Z. Diagnosis and treatment of accidental root perforations. *Endod Top* 2006; 13:95-107.
2. Ruddle JC. Nonsurgical endodontic retreatment. In: Cohen S, Burns RC, eds. Pathways of the pulp, 8th ed. St Louis: Mosby Inc, 2002:919.
3. Lee SJ, Monsef M, Torabinejad M. Sealing ability of a mineral trioxide aggregate for repair of lateral root perforations. J Endod 1993;19:541-4.
4. Oliveira MG, Xavier CB, Demarco FF, Pinheiro AL, Costa AT, Pozza DH.Comparative chemical study of MTA and Portland cements. *Braz Dent J* 2007;18(1):3-7.
5. Ber BS, Hatton JF, Stewart GP. Chemical modification of ProRoot MTA to improve handling characteristics and decrease setting time. *J Endod* 2007;33(10):1231-4.
6. Vanderweele RA, Schwartz SA, Beeson TJ. Effect of blood contamination on retention characteristics of MTA when mixed with different liquids. *J Endod* 2006;32(5):421-4.
7. Roberts HW, Toth JM, Berzins DW, Charlton DG. Mineral trioxide aggregate material use in endodontic treatment: a review of the literature. *Dent Mater* 2008; 24(2):149-64.
8. Ruddle CJ. Micro-endodontic nonsurgical retreatment. Dent Clin North Am. 1997;41:429-54.
9. ElDeeb ME, ElDeeb M, Tabibi A, et al. An evaluation of the use of amalgam, Cavit, and calcium hydroxide in the repair of furcation perforations. J Endod. 1982;8:459-66.
10. Himel VT, Brady J Jr, Weir J Jr. Evaluation of repair of mechanical perforations of the pulp chamber floor using biodegradable tricalcium phosphate or calcium hydroxide. J Endod. 1985;11:161-5.
11. Stromberg T, Hasselgren G, Bergstedt H. Endodontic treatment of traumatic root perforations in man: a clinical and roentgenological follow-up study. Sven Tandlak Tidskr. 1972;65:457-66.
12. Zou L, Liu J, Yin S: In vitro evaluation of the sealing ability of MTA used for the repair of furcation perforations with and without the use of an internal matrix. Oral Surg Oral Med Oral Pathol Oral Radiol Endod 2008;105:61-5.

GUIDELINES FOR SUBMISSION OF MANUSCRIPTS

About the Journal

Journal of Odontological Research, an official publication of Indira Gandhi Institute of Dental Sciences, Nellikuzhy P. O., Kothamangalam 686 691, Kerala, is a peer-reviewed journal published bi-annually in print format.

Scope of the journal

The journal will cover studies related to dentistry and applied basic subjects.

Submission of manuscripts

The manuscripts can be submitted under the categories of **Original Research, Review and Case reports. The guidelines and instructions for authors regarding the drafting and submitting the manuscripts are given below.** Kindly submit your valuable contributions as per the guidelines to the e-mail id **jorigids@gmail.com.**

The Editorial Process

A manuscript will be reviewed for possible publication with the understanding that it is being submitted to Journal of Odontological Research alone at that point in time and has not been published anywhere, simultaneously submitted, or already accepted for publication elsewhere. The journal expects that authors would authorize one of them to correspond with the Journal for all matters related to the manuscript. All manuscripts received are duly acknowledged. On submission, editors review all submitted manuscripts initially for suitability for formal review. Manuscripts with insufficient originality, serious scientific or technical flaws, or lack of a significant message are rejected before proceeding for formal peer-review.

Manuscripts that are found suitable for publication in Journal of Odontological Research are sent to two or more expert peer reviewers. The journal follows a double-blind review process, wherein the reviewers and authors are unaware of each other's identity. Every manuscript is also assigned to a member of the editorial team, who based on the comments from the reviewers takes a final decision on the manuscript. The comments and suggestions (acceptance/ rejection/ amendments in manuscript) received from reviewers are conveyed to the corresponding author. If required, the author is requested to provide a point by point response to reviewers' comments and submit a revised version of the manuscript. This process is repeated till reviewers and editors are satisfied with the manuscript.

Manuscripts accepted for publication are copy edited for grammar, punctuation, print style, and format. Page proofs are sent to the corresponding author.

Authorship Criteria

Each contributor should have participated sufficiently in the work to take public responsibility for appropriate portions of the content of the manuscript. The order of naming the contributors should be based on the relative contribution of the contributor towards the study and writing the manuscript. The journal prescribes a maximum number of

authors for the manuscripts. **The maximum number of authors for original research articles is six and for case reports and reviews is four.**

Conflicts of Interest/ Competing Interests

All authors of must disclose any and all conflicts of interest they may have with publication of the manuscript or an institution or product that is mentioned in the manuscript and/or is important to the outcome of the study presented. Authors should also disclose conflict of interest with products that compete with those mentioned in their manuscript.

Submission of Manuscripts

All manuscripts must be submitted on-line to the e-mail jorigids@gmail.com. Authors will have to pay for submission, processing or publication of articles. If you experience any problems, please contact the editorial office by e-mail. The submitted manuscripts that are not as per the "Instructions to Authors" would be returned to the authors for technical correction, before they undergo editorial/ peer-review. Generally, the manuscript should be submitted in the form of two separate files:

[1] **Title Page/First Page File/covering letter**:

This file should provide

1. The type of manuscript (original article, case report, review article, Letter to editor, Images, etc.) title of the manuscript, running title, names of all authors/ contributors (with their highest academic degrees, designation and affiliations) and name(s) of department(s) and/ or institution(s) to which the work should be credited, . All information which can reveal your identity should be here. Use text/rtf/doc files.
2. Source(s) of support in the form of grants, equipment, drugs, or all of these;
3. Acknowledgement, if any..
4. Conflicts of Interest of each author/ contributor. A statement of financial or other relationships that might lead to a conflict of interest, if that information is not included in the manuscript itself or in an authors' form
5. The name, address, e-mail, and telephone number of the corresponding author, who is responsible for communicating with the other authors about revisions and final approval of the proofs, if that information is not included on the manuscript itself.

[2] **Blinded Article file**: The main text of the article, beginning from Abstract till References (including tables) should be in this file. The file must not contain any mention of the authors' names or initials or the institution at which the study was done or acknowledgements. Page headers/running title can include the title but not the authors' names. Manuscripts not in compliance with the Journal's blinding policy will be returned to the corresponding author. Use rtf/doc files. Do not zip the files. **Limit the file size to 1 MB**. Do not incorporate images in the file. The pages should be numbered consecutively, beginning with the first page of the blinded article file.

[3] **Images**: Submit good quality color images. **Each image should be less than 4 MB in size**. Size of the image can be reduced by decreasing the actual height and width of the images (keep up to 1800 x 1200 pixels or 5-6 inches). Images can be submitted as jpeg files. Do not zip the files. Legends for the figures/images should be included at the end of the article file.

[4] **The contributors' / copyright transfer form** has to be submitted in original with the signatures of all the contributors within two weeks of submission via courier, fax or email as a scanned image. High resolution images (up to 5 MB each) can be sent by email.

Preparation of Manuscripts

Manuscripts must be prepared in accordance with "Uniform requirements for Manuscripts submitted to Biomedical Journals" developed by the International Committee of Medical Journal Editors (October 2008). The uniform requirements and specific requirement of Journal of Odontological Research are summarized below. Journal of Odontological Research accepts manuscripts written in English. For further details regarding the guidelines in drafting the manuscript for publication, log on to www.igids.org